



PATIENT PRESENTING CLINICAL SIGNS

Joey Ciasnocha History: Patient vomited 10 times yesterday. Was given Cerneia inj in hospital yesterday - patient then continued to vomit around 5 times overnight after inj.
Abnormal PE/Chem/CBC/UA Results:

SPECIES RADIOGRAPHIC STUDY OF THE ABDOMEN

Canine A complete set of radiographs of the abdomen is provided for review.

BREED RADIOGRAPHIC FINDINGS

Beagle Mix The surrounding bony structures are within normal limits.

SEX No abnormalities of the extraabdominal soft tissues are noted. The abdominal wall is smooth and thin.

Neutered Male The serosal detail is maintained throughout the peritoneal and retroperitoneal space.

The liver is appropriate in position, size and presents uniform opacity.

AGE The splenic head is in the anticipated position and within normal limits for size and opacity. The splenic body and tail are considered normal for position, size, shape and opacity.

16 Months

Both kidneys are seen and present with normal size, shape, delineation and opacity. The urinary bladder is in its anticipated position. No radiopaque calculi are noted throughout the upper and lower urinary tract.

INTERPRETED BY

Sebastian Schaub,
DVM Dr. med. vet.
DipECVDI

The stomach is in its anticipated position and contains a mild amount of fluid and gas.

HOSPITAL NAME

Truscott AH

The small intestinal loops are of even diameter and non-dilated, a small amount of gas is seen within the small intestinal loops. The supposed most distal aspect of the small intestinal tract contains a mild amount of foamy material.

The colon is seen in the expected position and presents with appropriate content.

REFERRING VET RADIOGRAPHIC DIAGNOSIS

Dr. Medhat Meawad • Empty stomach

INTERPRETATION OF THE FINDINGS & FURTHER RECOMMENDATIONS

INVOICE

12707

There is no evidence of radiopaque foreign material or signs for gastrointestinal mechanical obstruction. If clinical signs are refractory to empirical management, recommend either follow up radiographs or an abdominal ultrasound examination; in some cases a high ileus may lack classical radiographic signs of gastrointestinal mechanical obstruction.

DATE

8/24/21



PATIENT

Joey Ciasnocha

SPECIES

Canine

BREED

Beagle Mix

SEX

Neutered Male

AGE

16 Months

INTERPRETED BY

Sebastian Schaub,
DVM Dr. med. vet.
DipECVDI

HOSPITAL NAME

Truscott AH

REFERRING VET

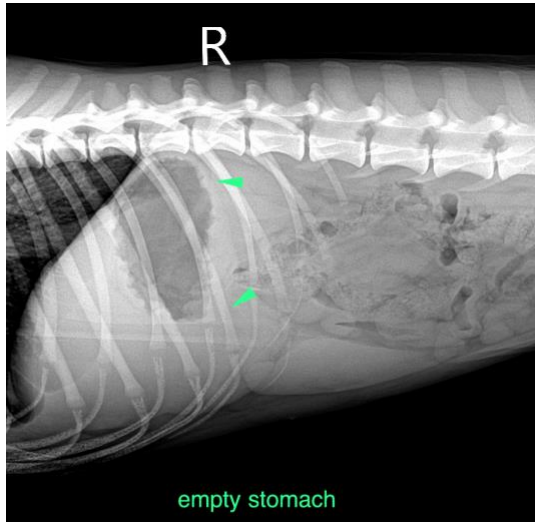
Dr. Medhat Meawad

INVOICE

12707

DATE

8/24/21



The information and recommendations provided are based on the images presented by the referring veterinarian. No evaluation can be communicated regarding pathology that was not visible in the image/video clips provided.

Thank you for this referral. If the clinical or image interpretation does not parallel your findings or if I can be of any further assistance please contact me.

Sebastian Schaub, Sebastian Schaub, DVM, Dr. med. vet. DipECVDI
sebast.schaub@gmail.com