



PATIENT

Cardi Harris

PRESENTING CLINICAL SIGNS

Patient has an enlarged heart and a grade 6/6 heart murmur.

SPECIES

Canine

COMPUTED TOMOGRAPHY OF THE THORAX

A high resolution pre- and post-contrast CT study of the thorax are provided for review.

BREED

Miniature Dachshund

COMPUTED TOMOGRAPHIC FINDINGS

The bony and surrounding soft tissue structures are within normal limits; the growth plates are age related open.

SEX

Female

The aortic arch is in a physiological position on the left side of the trachea. The left atrium and ventricle are prominent. In the post contrast CT study, the ductus arteriosus can be appreciated between the aorta and the main pulmonary artery with an isthmus before entering the main pulmonary artery.

AGE

8 Weeks, 6 Days

The lung parenchyma presents the expected architecture and generalized mild dystelectasis.

Small incidental gas pockets are seen within the esophageal lumen, there is no evidence of abnormal dilation.

INTERPRETED BY

Sebastian Schaub, DVM
Dr. med. vet. DipECVDI

COMPUTED TOMOGRAPHIC DIAGNOSIS

- Persistent ductus arteriosus (PDA)
- Generalized left cardiac enlargement without evidence of decompensation

HOSPITAL NAME

Neel Veterinary
Hospital

INTERPRETATION OF THE FINDINGS & FURTHER RECOMMENDATIONS

The CT study is compatible with PDA and secondary left sided volume overload due to blood recirculating from the aorta through the lung. Recommend a cardiac echo to confirm the finding and rule out other abnormalities of the heart not appreciated by CT and shunt reversion (Eisenmenger reaction) - as contraindication for closure of the PDA. Either surgical or interventional closure of the PDA is the therapy of choice.

REFERRING VET

Dr. Deepan Kishore

INVOICE

47127

DATE

8-24-21



PATIENT

Cardi Harris

SPECIES

Canine

BREED

Miniature Dachshund

SEX

Female

AGE

8 Weeks, 6 Days

INTERPRETED BY

Sebastian Schaub, DVM
Dr. med. vet. DipECVDI

HOSPITAL NAME

Neel Veterinary
Hospital

REFERRING VET

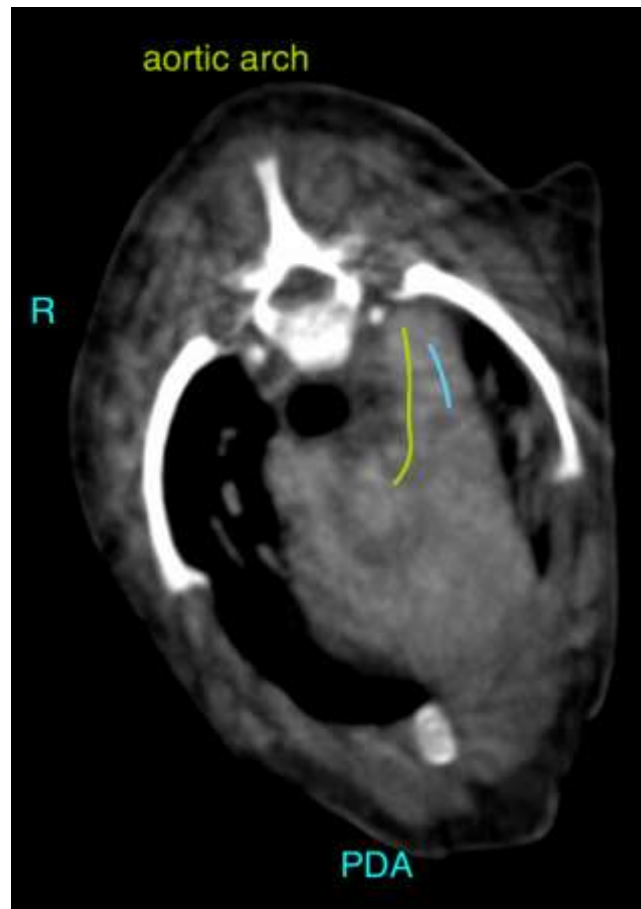
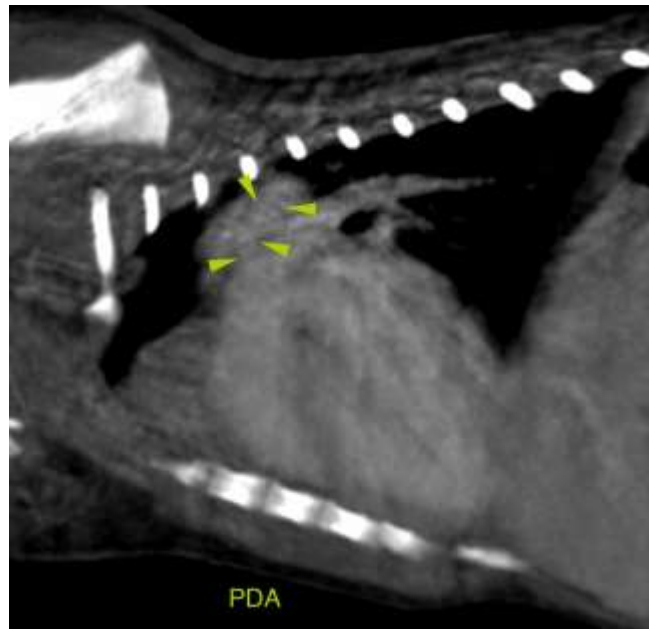
Dr. Deepan Kishore

INVOICE

47127

DATE

8-24-21





PATIENT

Cardi Harris

The information and recommendations provided are based on the images presented by the referring veterinarian. No evaluation can be communicated regarding pathology that was not visible in the image/video clips provided.

SPECIES

Canine

Thank you for this referral. If the clinical or image interpretation does not parallel your findings or if I can be of any further assistance please contact me.

Sebastian Schaub, Sebastian Schaub, DVM, Dr. med. vet. DipECVDI
sebast.schaub@gmail.com

BREED

Miniature Dachshund

SEX

Female

AGE

8 Weeks, 6 Days

INTERPRETED BY

Sebastian Schaub, DVM
Dr. med. vet. DipECVDI

HOSPITAL NAME

Neel Veterinary
Hospital

REFERRING VET

Dr. Deepan Kishore

INVOICE

47127

DATE

8-24-21