



PATIENT

Bella Phillip

PRESENTING CLINICAL SIGNS

P here for urinating out of box. O noticed a lump on her right part of chest. Sometimes eating too much. O does not how old cat is. Drinking ok. No other concerns.

Abnormal PE/Chem/CBC/UA Results: FELV/FIV test- Negative Rabies vax 1 yr FVRCP vax ½

SPECIES

Feline

RADIOGRAPHIC STUDY OF THE THORAX & ABDOMEN

An overview study including the thorax and abdomen in two imaging planes are provided for review.

BREED

Domestic Short Hair

RADIOGRAPHIC FINDINGS

Thorax

SEX

Female

At the cranioventral abdominal wall, a roundish subcutaneous mass is seen, measuring approximately 1.5 cm in size. The subcutaneous mass appears to be level with a mammary gland.

The extrathoracic soft tissues present homogeneous without abnormalities.

AGE

N/A

The heart is of normal size and shape, there is no evidence of cardiac chamber or vascular enlargement. The pulmonary vasculature is within normal limits.

The cranial mediastinum presents the expected soft tissue opacity.

INTERPRETED BY

Sebastian Schaub, DVM
Dr. med. vet. DipECVDI

The trachea is normal in diameter and presents the anticipated course. The luminal outline of the trachea is smooth.

The bronchial tree presents with thin walls and tapers uniformly towards the periphery as expected.

HOSPITAL NAME

Animal Paradise
Hospital

The lung parenchyma presents the expected architecture and opacity; the intrapulmonary vascular branching is seen up to the third order lung vessels.

The diaphragm is well delineated with even surface and the expected mild cranial bulging of the diaphragmatic cupola.

REFERRING VET

Dr. Mostafa Elshafie

Abdomen

The surrounding bony structures are within normal limits.

INVOICE

47124

No abnormalities of the extraabdominal soft tissues are noted. The abdominal wall is smooth and thin.

The serosal detail is maintained throughout the peritoneal and retroperitoneal space.

DATE

8-24-21

The liver is appropriate in position, size and presents uniform opacity.

The splenic head is in the anticipated position and within normal limits for size and opacity.

Both kidneys are seen and present with normal size, shape, delineation and opacity. The urinary



PATIENT

Bella Phillip

bladder is in its anticipated position. No radiopaque calculi are noted throughout the upper and lower urinary tract.

The stomach is in its anticipated position and presents normal content.

SPECIES

Feline

The small intestinal loops are of even diameter and non-dilated, a small amount of gas is seen within the small intestinal loops and considered within normal limits.

The colon is seen in the expected position and presents with appropriate content.

BREED

Domestic Short Hair

RADIOGRAPHIC DIAGNOSIS

- Mild obesity
- Possible mammary mass
- Structural normal thorax
- Structural normal abdomen

SEX

Female

INTERPRETATION OF THE FINDINGS & FURTHER RECOMMENDATIONS

The mass at the cranioventral aspect of the abdominal wall is concerning for a mass originating from the mammary gland such as carcinoma. Fibrosarcoma or other non-specific subcutaneous nodules are a potential. Excision biopsy of the mass is considered beneficial.

AGE

N/A

No radiographic abnormalities of the urinary tract are appreciated, consider a complete urinalysis and abdominal ultrasound examination for further definition.

INTERPRETED BY

Sebastian Schaub, DVM
Dr. med. vet. DipECVDI

HOSPITAL NAME

Animal Paradise
Hospital

REFERRING VET

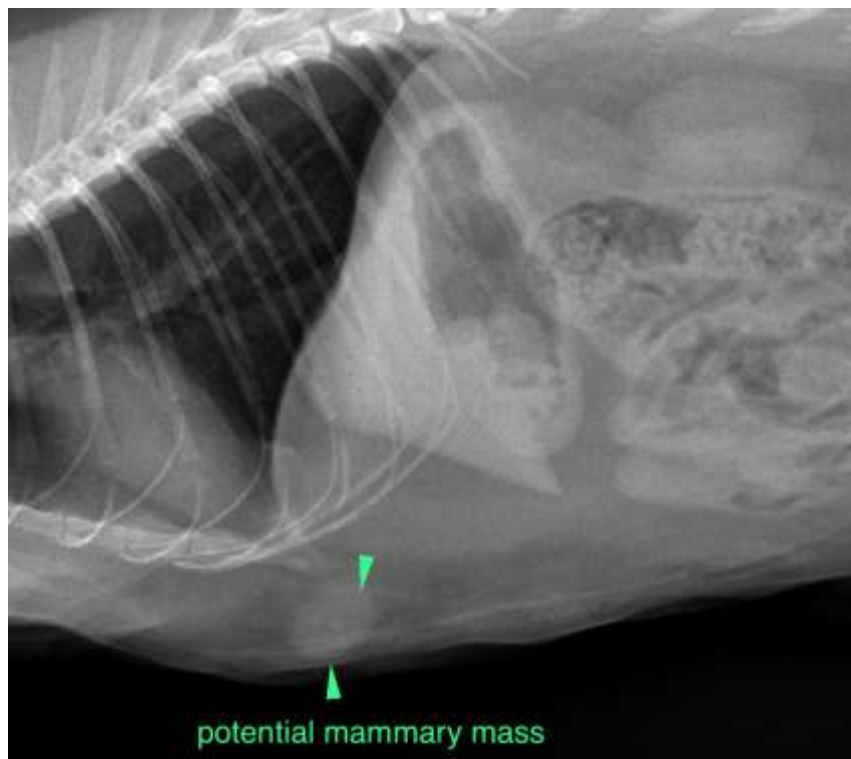
Dr. Mostafa Elshafie

INVOICE

47124

DATE

8-24-21





PATIENT

Bella Phillip

The information and recommendations provided are based on the images presented by the referring veterinarian. No evaluation can be communicated regarding pathology that was not visible in the image/video clips provided.

SPECIES

Feline

Thank you for this referral. If the clinical or image interpretation does not parallel your findings or if I can be of any further assistance please contact me.

BREED

Domestic Short Hair

Sebastian Schaub, Sebastian Schaub, DVM, Dr. med. vet. DipECVDI
sebast.schaub@gmail.com

SEX

Female

AGE

N/A

INTERPRETED BY

Sebastian Schaub, DVM
Dr. med. vet. DipECVDI

HOSPITAL NAME

Animal Paradise
Hospital

REFERRING VET

Dr. Mostafa Elshafie

INVOICE

47124

DATE

8-24-21