



PATIENT PRESENTING CLINICAL SIGNS

Henry Besencski 5 years old indoor cat, heavy breathing and wheezing for more than a month, harsh sound on the trachea and chest and abdominal breathing

SPECIES RADIOGRAPHIC STUDY OF THE THORAX

Feline A right lateral projection of the thorax is provided for review.

RADIOGRAPHIC FINDINGS

BREED The surrounding bony structures are within normal limits.

Domestic Shorthair The extrathoracic soft tissues present homogeneous without abnormalities.

SEX A significant amount of soft tissue material is appreciated in the pleural cavity. The lung lobes are retracted from the thoracic wall, present a significant decreased volume, generalized ground glass opacity and rounded margins. The pleural soft tissue material is effacing the cardiac silhouette.

RADIOGRAPHIC DIAGNOSIS

- Male
- Marked pleural effusion

AGE

5 Years

INTERPRETED BY

Sebastian Schaub, DVM
Dr. med. vet. DipECVDI

INTERPRETATION OF THE FINDINGS & FURTHER RECOMMENDATIONS

The radiographic study presents a significant amount of pleural effusion, an underlying cause for the pleural effusion cannot be specified in the current radiographic study – transudate versus exudate are considerations. Possible causes include cardiac disease, infection (e.g. pyothorax, FIP), inflammation (e.g. vasculitis), chylothorax, hypalbuminemia, coagulopathy, neoplasia. Further workup warrants tapping of the pleural effusion including complete fluid analysis.

HOSPITAL NAME

Truscott Animal
Hospital

REFERRING VET

Dr. Hala Gerges

INVOICE

59900

DATE

8-23-23



PATIENT

Henry Besenscki

SPECIES

Feline

BREED

Domestic Shorthair

SEX

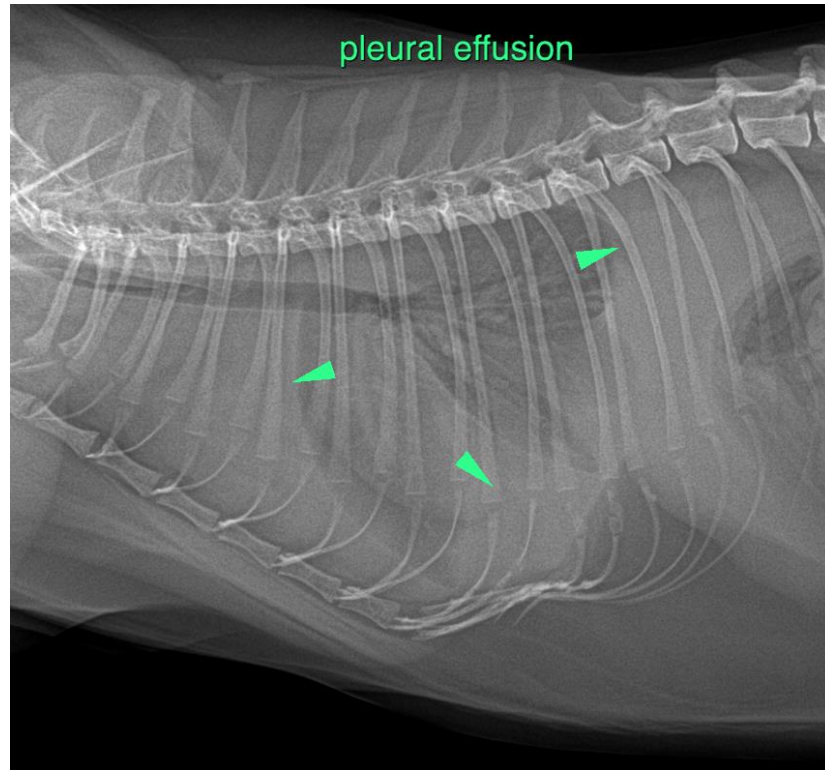
Male

AGE

5 Years

INTERPRETED BY

Sebastian Schaub, DVM
Dr. med. vet. DipECVDI



HOSPITAL NAME

Truscott Animal
Hospital

The information and recommendations provided are based on the images presented by the referring veterinarian/sonographer. No evaluation can be communicated regarding pathology that was not visible in the image/video clips provided.

Thank you for this referral. If the clinical or image interpretation does not parallel your findings or if I can be of any further assistance please contact me.

REFERRING VET

Dr. Hala Gerges

Sebastian Schaub, Sebastian Schaub, DVM, Dr. med. vet. DipECVDI
info@sonopath.com

INVOICE

59900

DATE

8-23-23