



PATIENT PRESENTING CLINICAL SIGNS

Zanna Whitaker 3 months persistent coughing, worsening last few weeks mass noted on radiographs no mets seen on AUS

SPECIES COMPUTED TOMOGRAPHY OF THE THORAX

Canine A high resolution pre- and post-contrast CT study of the thorax is provided for review.

COMPUTED TOMOGRAPHIC FINDINGS

BREED Multifocal mild spondylosis formation is seen along the thoracic spine.

West Highland Terrier The sternal, cranial mediastinal and tracheobronchial lymph nodes are small elongated with a normal short-to-long-axis-ratio is < 0.5, the attenuation and contrast enhancement pattern is uniform and considered within normal limits.

SEX In the caudal aspect of the right cranial lung lobe, a soft tissue attenuating, ovoidal shaped mass with mild interspersed granular mineralization is visible, measuring 9.6 x 5.4 x 8.1 cm in size. Associated bronchi of the right cranial lung lobe are deviated and compressed. A mass effect on the right middle and caudal lung lobe is seen, with complete consolidation of the right middle lung lobe. The heart is deviated to the left by the mass effect.

FS

AGE In the caudodorsal aspect of the right caudal lung lobe, a well-defined, soft tissue attenuating nodule, measuring 5 mm in diameter is seen. The left lung lobes present a decreased volume and regions of dystelectasis.

12 Years

INTERPRETED BY Small incidental gas pockets are seen within the esophageal lumen, there is no evidence of abnormal dilation.

Sebastian Schaub, DVM
Dr. med. vet. DipECVDI

In the gallbladder, multiple, mineral attenuating roundish calculi are visible.

The left adrenal gland is moderately enlarged, measuring 16 mm in diameter.

HOSPITAL NAME COMPUTED TOMOGRAPHIC DIAGNOSIS

Mountain West
Veterinary Hospital

- Pulmonary mass right cranial lung lobe
- Solitary nodular lung lesion right caudal lung lobe
- Compression atelectasis right middle lung lobe
- Left sided adrenomegaly
- Cholecystolithiasis without signs of obstruction
- Spondylosis deformans

REFERRING VET

Dr. Jeff Simmons

INTERPRETATION OF THE FINDINGS & FURTHER RECOMMENDATIONS

INVOICE The pulmonary mass is likely originating from the right cranial lung lobe and primary pulmonary neoplasia is the diagnosis – such as bronchogenic/bronchoalveolar carcinoma. FNA sampling of the pulmonary mass can be used as advanced diagnostic tool.

53665

DATE The solitary pulmonary nodule in the caudal lung lobe is concerning for metastatic spread, other potentials for a solitary pulmonary mass include granuloma, fibrosis, mucus impaction/round pneumonia, cyst.

8-23-22



PATIENT

Zanna Whitaker

If surgery is performed, consider partial lobectomy of the caudodorsal part of the right caudal lung lobe as well.

The enlarged left adrenal gland can be a sequela to (non)functional macronodular hyperplasia or neoplastic transformation (e.g. adenoma, adenocarcinoma, pheochromocytoma).

SPECIES

Canine

BREED

West Highland
Terrier

SEX

FS

AGE

12 Years

INTERPRETED BY

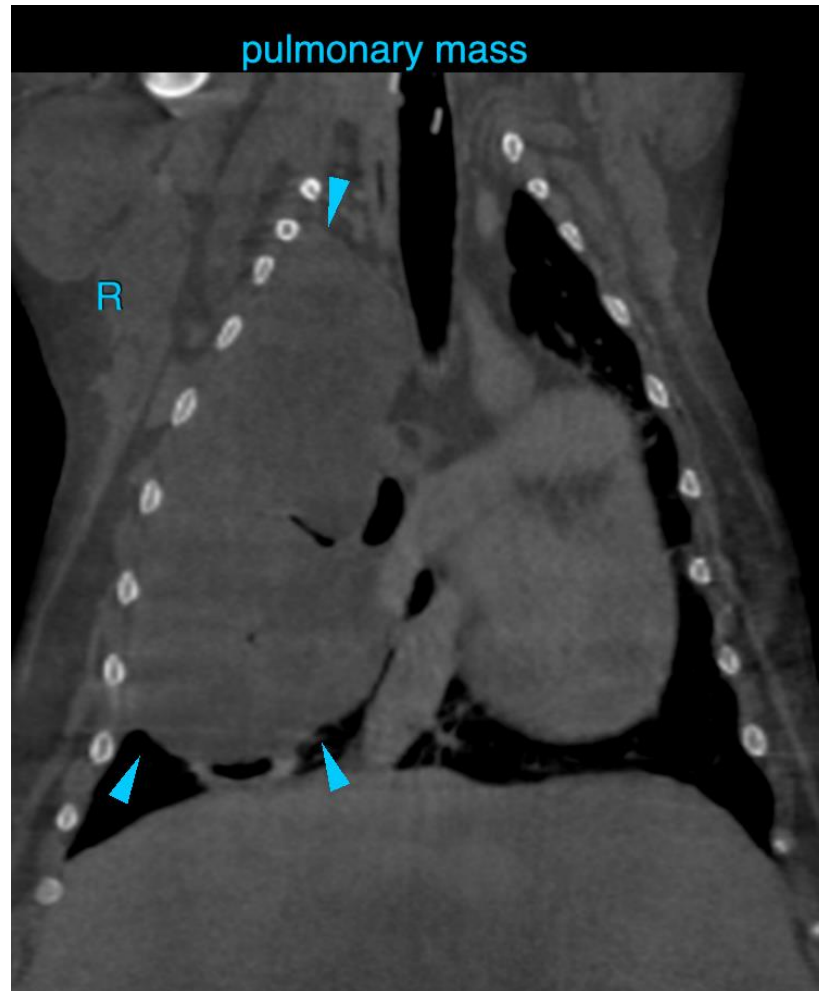Sebastian Schaub, DVM
Dr. med. vet. DipECVDI

HOSPITAL NAME

Mountain West
Veterinary Hospital

REFERRING VET

Dr. Jeff Simmons



INVOICE

53665

DATE

8-23-22



PATIENT

Zanna Whitaker

SPECIES

Canine

BREED

West Highland
Terrier

SEX

FS

AGE

12 Years

INTERPRETED BY

Sebastian Schaub, DVM
Dr. med. vet. DipECVDI

HOSPITAL NAME

Mountain West
Veterinary Hospital

REFERRING VET

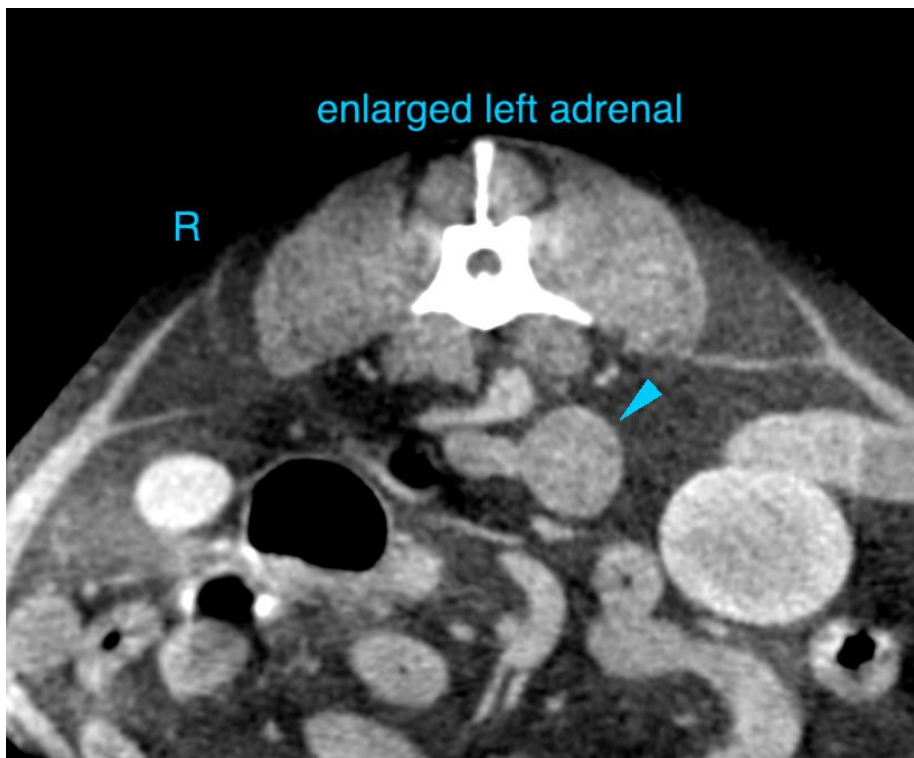
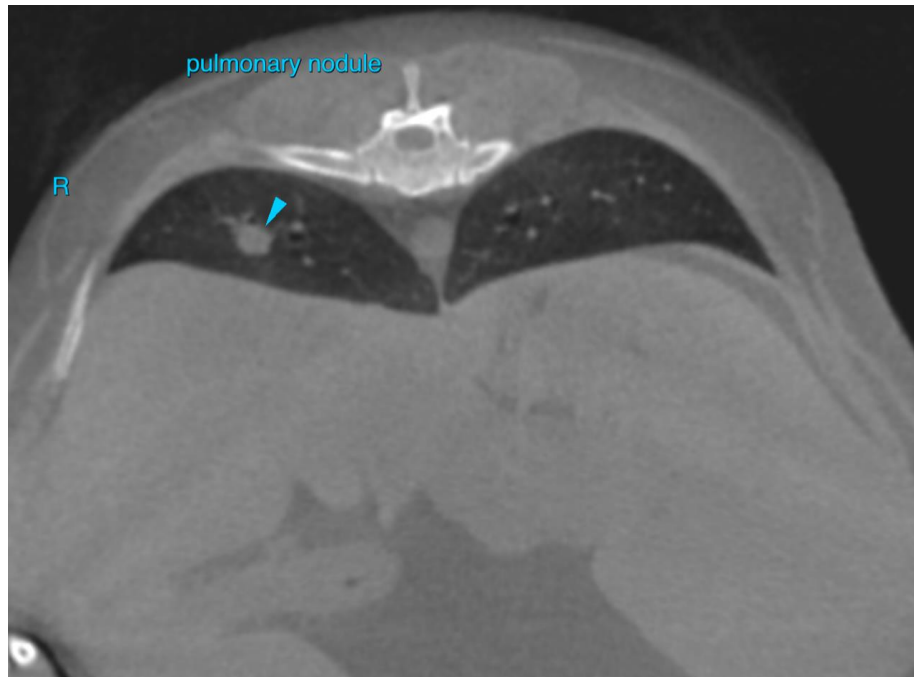
Dr. Jeff Simmons

INVOICE

53665

DATE

8-23-22





PATIENT

Zanna Whitaker

SPECIES

Canine

BREED

West Highland
Terrier

SEX

FS

AGE

12 Years

INTERPRETED BY

Sebastian Schaub, DVM
Dr. med. vet. DipECVDI

HOSPITAL NAME

Mountain West
Veterinary Hospital

REFERRING VET

Dr. Jeff Simmons

INVOICE

53665

DATE

8-23-22

The information and recommendations provided are based on the images presented by the referring veterinarian/sonographer. No evaluation can be communicated regarding pathology that was not visible in the image/video clips provided.

Thank you for this referral. If the clinical or image interpretation does not parallel your findings or if I can be of any further assistance please contact me.

Sebastian Schaub, Sebastian Schaub, DVM, Dr. med. vet. DipECVDI
sebast.schaub@gmail.com