

PATIENT

Autumn Bob Osborn

PRESENTING CLINICAL SIGNS

Increased lung sounds, no murmur on both sides.

SPECIES

Feline

RADIOGRAPHIC STUDY OF THE THORAX

Radiographs of the thorax in two orthogonal imaging planes are provided for review.

BREED

DSH

RADIOGRAPHIC FINDINGS

The body condition score is 7/9.

Multifocal mild spondylosis formation is seen along the thoracic spine.

SEX

FS

The extrathoracic soft tissues present homogeneous without abnormalities.

A small gas depot is seen in the esophagus, dorsal to the intrathoracic tracheal segment.

The heart is of normal size and shape, there is no evidence of cardiac chamber or vascular enlargement. The pulmonary vasculature is within normal limits.

The trachea is normal in diameter and presents the anticipated course. The luminal outline of the trachea is smooth.

AGE

7 Years, 11 Months

The bronchial tree presents with thin walls and tapers uniformly towards the periphery as expected.

The lung parenchyma presents the expected architecture and opacity; the intrapulmonary vascular branching is seen up to the third order lung vessels.

The diaphragm is well delineated with even surface and the expected mild cranial bulging of the diaphragmatic cupola.

INTERPRETED BY

Sebastian Schaub, DVM
Dr. med. vet. DipECVDI

RADIOGRAPHIC DIAGNOSIS

- Mild obesity
- Mild aerophagia – suspect due to stress

HOSPITAL NAME

Reid Veterinary
Hospital

INTERPRETATION OF THE FINDINGS & FURTHER RECOMMENDATIONS

The radiographic study of the thorax presents without abnormalities but the mild obesity of the patient. There are no radiographic signs for bronchitis/broncho-pneumonitis.

REFERRING VET

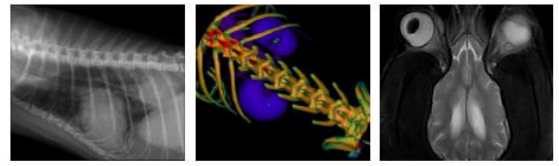
Dr. Diane Heider

INVOICE

53663

DATE

8-23-22



PATIENT

Autumn Bob Osborn

The information and recommendations provided are based on the images presented by the referring veterinarian/sonographer. No evaluation can be communicated regarding pathology that was not visible in the image/video clips provided.

SPECIES

Feline

Thank you for this referral. If the clinical or image interpretation does not parallel your findings or if I can be of any further assistance please contact me.

Sebastian Schaub, Sebastian Schaub, DVM, Dr. med. vet. DipECVDI
sebast.schaub@gmail.com

BREED

DSH

SEX

FS

AGE

7 Years, 11 Months

INTERPRETED BY

Sebastian Schaub, DVM
Dr. med. vet. DipECVDI

HOSPITAL NAME

Reid Veterinary
Hospital

REFERRING VET

Dr. Diane Heider

INVOICE

53663

DATE

8-23-22