



PATIENT PRESENTING CLINICAL SIGNS

Smokey Lee History: Smokey came in last Friday as she vomited 3 times and looks is in pain. X-ray done on Friday and sent home with Sulcrate 3 times daily and Cerenia SQ injection. Today the owner called back with a concern that Smokey eating less (50%) , no vomiting, pee more and only one bowel movement thins morning since Friday. The owner concerned about gastric foreign body.

SPECIES

Feline Abnormal PE/Chem/CBC/UA Results: No recent BW

RADIOGRAPHIC STUDY OF THE ABDOMEN

BREED

DSH Radiographs of the abdomen in three imaging planes are provided for review.

RADIOGRAPHIC FINDINGS

SEX

The surrounding bony structures are within normal limits.

Spayed Female

No abnormalities of the extraabdominal soft tissues are noted. The abdominal wall is smooth and thin.

AGE

The serosal fat presents a mil soft tissue striation medial to the spleen. A well-defined peripherally mineralized roundish body is seen in the left mid abdomen.

11 Months

The liver is appropriate in position, size and presents uniform opacity.

INTERPRETED BY

The splenic head is in the anticipated position and within normal limits for size and opacity.

Sebastian Schaub,
DVM Dr. med. vet.
DipECVDI

Both kidneys are seen and present with normal size, shape, delineation and opacity. The urinary bladder is in its anticipated position. No radiopaque calculi are noted throughout the upper and lower urinary tract.

HOSPITAL NAME

The stomach is in its anticipated position and contains foamy material.

Brittany Glen AH

Multiple segments of the small intestinal loops contain a mild amount of gas, arranged in a string of pearl like pattern and the respective segments appears corrugated.

REFERRING VET

The colon is seen in the expected position and presents with appropriate content.

Dr. Boktor

RADIOGRAPHIC DIAGNOSIS

INVOICE

- Corrugated small intestinal loops
- Foamy material in stomach
- Small nodular fat necrosis left abdomen

12674

INTERPRETATION OF THE FINDINGS & FURTHER RECOMMENDATIONS

DATE

8/23/21



PATIENT

Smokey Lee

The intestinal pattern indicates hypermotility/spasticity of the small intestinal loops which can be secondary to stress or enteritis. There are no signs for pathological plication. The material in the stomach is considered as normal ingesta, but if there is a history of recent intake of foreign material such as fabric material. There is no evidence of radiopaque foreign material or signs for gastrointestinal mechanical obstruction.

SPECIES

Feline

If clinical signs are refractory to empirical therapy, consider follow up radiographs or a complete abdominal ultrasound examination. If not done so yet, complete blood work is recommended.

BREED

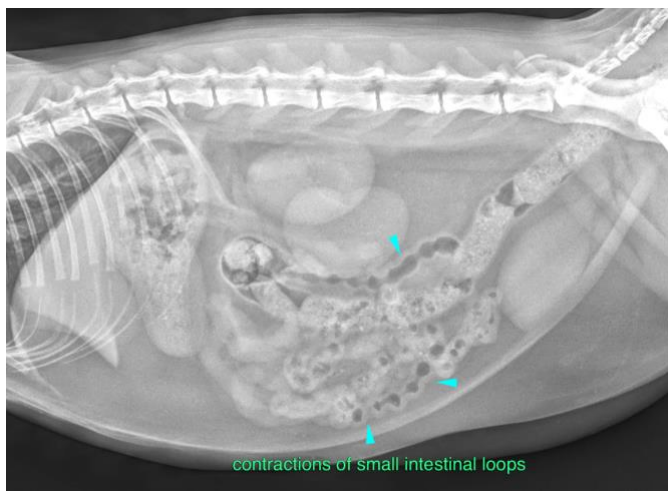
DSH

SEX

Spayed Female

AGE

11 Months



INTERPRETED BY

Sebastian Schaub,
DVM Dr. med. vet.
DipECVDI

The information and recommendations provided are based on the images presented by the referring veterinarian. No evaluation can be communicated regarding pathology that was not visible in the image/video clips provided.

Thank you for this referral. If the clinical or image interpretation does not parallel your findings or if I can be of any further assistance please contact me.

HOSPITAL NAME

Brittany Glen AH

Sebastian Schaub, Sebastian Schaub, DVM, Dr. med. vet. DipECVDI
sebast.schaub@gmail.com

REFERRING VET

Dr. Boktor

INVOICE

12674

DATE

8/23/21