



PATIENT PRESENTING CLINICAL SIGNS

PATIENT Miss Kitty Zelinka
SPECIES Feline
BREED DSH
SEX Spayed Female
AGE 9 Years

History: Client noted facial swelling and mild head tilt last night to the R. n In clinic slightly holds R ear down and mild R head tilt at times. Ear canal normal but cannot see to tympanum. No circling and normal mentation and movements. Fractured 204 in 2016, but no pulp exposure, so was monitoring. Now there is no visible tooth and ~2cm firm swelling that bleeds when palpated. Shop cat. Thinks might be eating less hard food (free fed), but eating canned food well.

Abnormal PE/Chem/CBC/UA Results: 204 site 2cm firm swelling bleeds on gentle palpation. Mild L facial swelling. Mild R head tilt, cannot see to tympanum but normal ear canal. No 3rd eyelid prolapse or recent vaccines, meds.

RADIOGRAPHIC STUDY OF THE SKULL

A complete set of radiographs of the skull is provided for review.

RADIOGRAPHIC FINDINGS

Triadan 204 is absent. In the lateral projections, a hyperdense body, presenting in the shape of the tooth root of absent triadan 204 is visible within the alveolar bone.

The tympanic bullae are aerated and present a smooth osseous lining. The external ear canals are aerated.

No additional abnormalities are appreciated.

RADIOGRAPHIC DIAGNOSIS

- Retained tooth root 204

INTERPRETATION OF THE FINDINGS & FURTHER RECOMMENDATIONS

The current CT study presents without specific abnormalities but the retained toot of triadan 204. As there is a clinical swelling present, recommend FNA sampling to rule out malignancy. No abnormalities are appreciated explaining the head tilt. A CT study of the skull can be considered as an advanced imaging modality.

INVOICE

12698

DATE

8/23/21

INTERPRETED BY

Sebastian Schaub,
 DVM Dr. med. vet.
 DipECVDI

HOSPITAL NAME

Lomsnes VH

REFERRING VET

Dr. Hayley Biederbeck



PATIENT

Miss Kitty Zelinka

SPECIES

Feline

BREED

DSH

SEX

Spayed Female

AGE

9 Years

INTERPRETED BY

Sebastian Schaub,
DVM Dr. med. vet.
DipECVDI

HOSPITAL NAME

Lomsnes VH

REFERRING VET

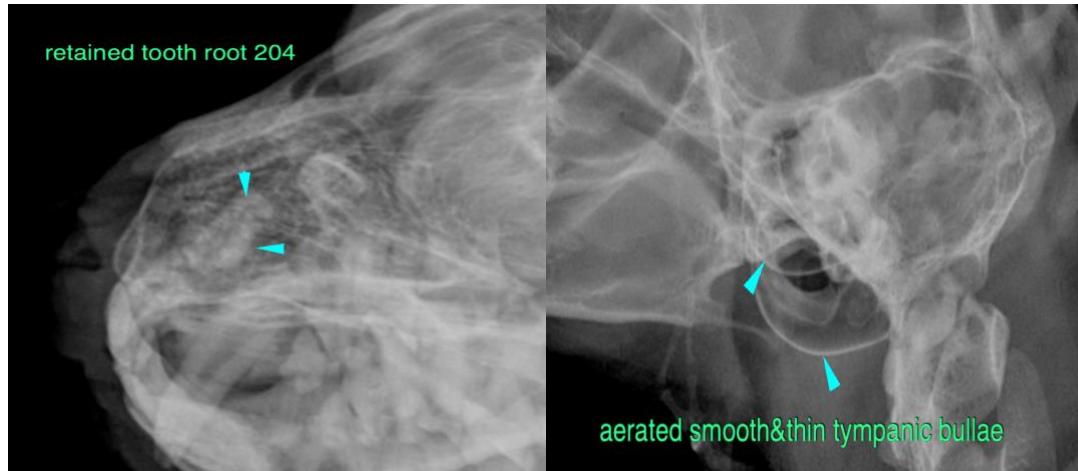
Dr. Hayley Biederbeck

INVOICE

12698

DATE

8/23/21



SEX The information and recommendations provided are based on the images presented by the referring veterinarian. No evaluation can be communicated regarding pathology that was not visible in the image/video clips provided.

AGE Thank you for this referral. If the clinical or image interpretation does not parallel your findings or if I can be of any further assistance please contact me.

Sebastian Schaub, Sebastian Schaub, DVM, Dr. med. vet. DipECVDI
sebast.schaub@gmail.com