



PATIENT

Abby Caldwell

PRESENTING CLINICAL SIGNS

History: the X-rays not very clear, possible one puppy in the lateral view, not obvious in the V/D
Abnormal PE/Chem/CBC/UA Results:

SPECIES

Canine

RADIOGRAPHIC STUDY OF THE ABDOMEN

A complete set of radiographs of the abdomen is provided for review.

BREED

Bulldog English Mix

RADIOGRAPHIC FINDINGS

The surrounding bony structures are within normal limits.

SEX

Female

No abnormalities of the extraabdominal soft tissues are noted. The abdominal wall is smooth and thin.
The abdomen is moderately distended. Two large soft tissue structures are seen in the right and left aspect of the abdomen containing mild mineralized fetal skeletons.

AGE

2 Years

The serosal detail is maintained throughout the peritoneal and retroperitoneal space.
The liver is appropriate in position, size and presents uniform opacity.
The splenic head is in the anticipated position and within normal limits for size and opacity.

INTERPRETED BY

Sebastian Schaub,
DVM Dr. med. vet.
DipECVDI

Both kidneys are seen and present with normal size, shape, delineation and opacity. The urinary bladder is in its anticipated position. No radiopaque calculi are noted throughout the upper and lower urinary tract.
The structures of the intestinal tract are displaced dorsally by the mass effect of the enlarged uterus.

HOSPITAL NAME

St. Catharine's AH

RADIOGRAPHIC DIAGNOSIS

- Gravid uterus

REFERRING VET

Dr. Bekhit

INTERPRETATION OF THE FINDINGS & FURTHER RECOMMENDATIONS

At least three complete fetal skeletons can be appreciated. At this point there is only mild mineralization of the fetal skeletal structures, suspect approximately 40th day of gestation, and the odds are high that there are more than the clearly seen three fetuses. Follow up radiographs in one week can be considered as progressive mineralization will increase visibility of the fetal skeletal structures.

INVOICE

12703

DATE

8/23/21



PATIENT

Abby Caldwell

SPECIES

Canine

BREED

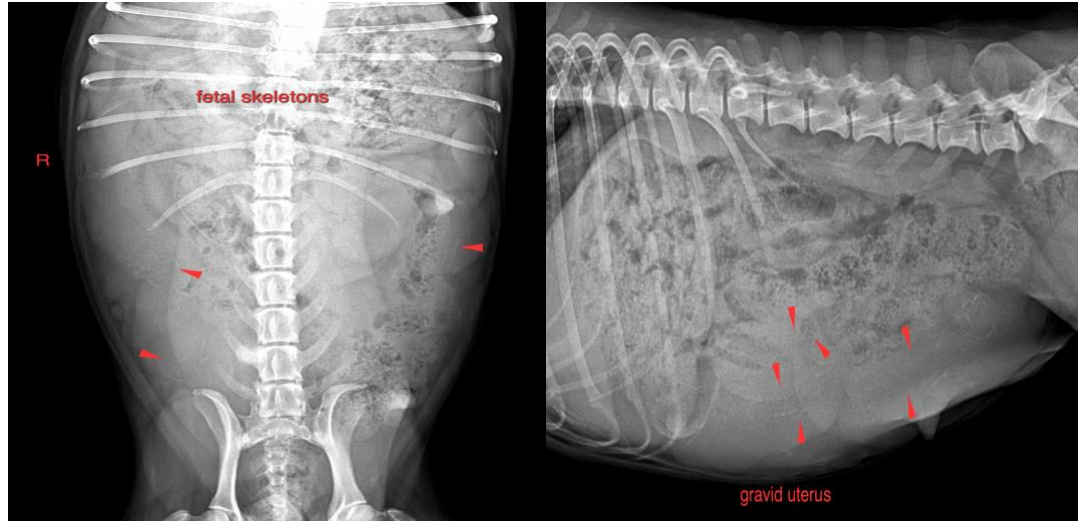
Bulldog English Mix

SEX

Female

AGE

2 Years



The information and recommendations provided are based on the images presented by the referring veterinarian. No evaluation can be communicated regarding pathology that was not visible in the image/video clips provided.

Thank you for this referral. If the clinical or image interpretation does not parallel your findings or if I can be of any further assistance please contact me.

Sebastian Schaub, Sebastian Schaub, DVM, Dr. med. vet. DipECVDI
sebast.schaub@gmail.com

INTERPRETED BY

Sebastian Schaub,
DVM Dr. med. vet.
DipECVDI

HOSPITAL NAME

St. Catharine's AH

REFERRING VET

Dr. Bekhit

INVOICE

12703

DATE

8/23/21