



**PATIENT PRESENTING CLINICAL SIGNS**

Zoi Czechowicz favoring left hind leg / grade 2 patella luxation/ no drawer sign detected

**RADIOGRAPHIC STUDY OF THE PELVIS AND STIFLE JOINTS**

**SPECIES** Radiographs of the pelvis and the stifle joints are provided for review.

Canine **RADIOGRAPHIC FINDINGS**

The osseous structures have a breed specific chondrodystrophic conformation.

**BREED** The osseous and surrounding soft tissue structures of the pelvis are within normal limits. Both coxofemoral joints present smooth osseous margins and congruent joint spaces.

Maltese

The patella of the left stifle joint is superimposed on the medial femoral condyle. Both stifle joints present smooth osseous margins and without signs of intracapsular soft tissue swelling.

**SEX** **RADIOGRAPHIC DIAGNOSIS**

- Female
- Left sided medial patellar luxation
  - Normal pelvis & coxofemoral joints
  - Normal right stifle joint

**AGE**

5 Years

**INTERPRETATION OF THE FINDINGS & FURTHER RECOMMENDATIONS**

**INTERPRETED BY**

Depending on the duration of clinical signs the medial patellar luxation can be a source for left hind limb lameness – will expect chronic (intermittent) left hind limb lameness. No additional abnormalities are appreciated.

Sebastian Schaub, DVM  
Dr. med. vet. DipECVDI

**HOSPITAL NAME**

Tenafly Vet Center

**REFERRING VET**

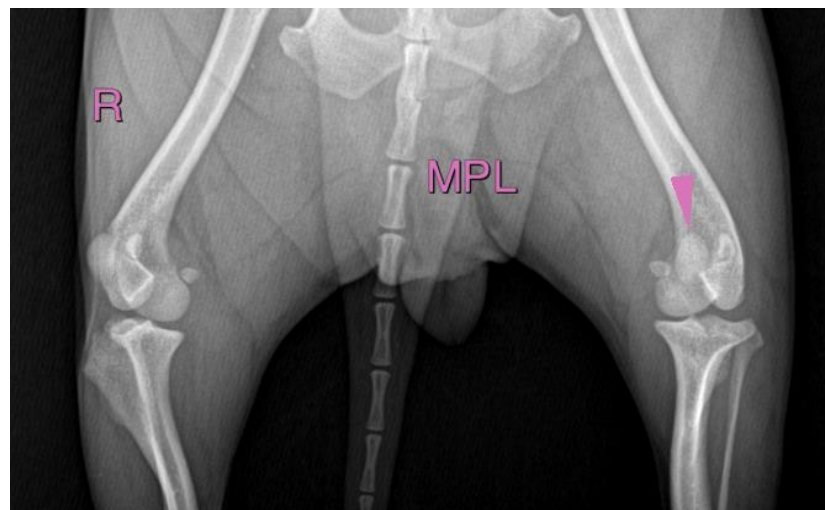
Kyoung Han

**INVOICE**

59868

**DATE**

8-22-23





**PATIENT** The information and recommendations provided are based on the images presented by the referring veterinarian/sonographer. No evaluation can be communicated regarding pathology that was not visible in the image/video clips provided.

Zoi Czechowicz

Thank you for this referral. If the clinical or image interpretation does not parallel your findings or if I can be of any further assistance please contact me.

**SPECIES**

Canine

**Sebastian Schaub**, Sebastian Schaub, DVM, Dr. med. vet. DipECVDI  
[info@sonopath.com](mailto:info@sonopath.com)

**BREED**

Maltese

**SEX**

Female

**AGE**

5 Years

**INTERPRETED BY**

Sebastian Schaub, DVM  
Dr. med. vet. DipECVDI

**HOSPITAL NAME**

Tenafly Vet Center

**REFERRING VET**

Kyoung Han

**INVOICE**

59868

**DATE**

8-22-23