



**PATIENT PRESENTING CLINICAL SIGNS**

Remi Bott Tawny said that he's been dry hacking and sometimes he produces clear bile. Remi can sleep for a while, then he'll start coughing and it'll go away. Tawny said that no other dogs in the house seem to be coughing. She said that he's not been sneezing, but he is panting a lot and having discharge coming from his nose.

**SPECIES**

Canine

Abnormal PE/Chem/CBC/UA Results: scaly skin on head and ears scaly skin on head elbow and paws

**RADIOGRAPHIC STUDY OF THE THORAX**

**BREED**

Radiographs of the thorax in three imaging planes are provided for review.

Pomeranian

**RADIOGRAPHIC FINDINGS**

The surrounding bony structures are within normal limits.

**SEX**

The extrathoracic soft tissues present homogeneous without abnormalities.

Male

In the right hemithorax, pleural fissure lines are visible.

**AGE**

3 Years, 2 Months

The heart is of normal size and shape, there is no evidence of cardiac chamber or vascular enlargement. The pulmonary vasculature is within normal limits.

The cranial mediastinum presents the expected soft tissue opacity. The mediastinal width is less than twice the width of the vertebral column at the same level.

**INTERPRETED BY**

The caudal cervical and the intrathoracic segment of the trachea are significantly dorsoventrally flattened.

Sebastian Schaub, DVM  
Dr. med. vet. DipECVDI

The bronchial tree presents with thin walls and tapers uniformly towards the periphery as expected.

**HOSPITAL NAME**

Elizabeth Animal  
Hospital

The lung parenchyma presents the expected architecture and opacity; the intrapulmonary vascular branching is seen up to the third order lung vessels.

The diaphragm is well delineated with even surface and the expected mild cranial bulging of the diaphragmatic cupola.

**RADIOGRAPHIC DIAGNOSIS**

**REFERRING VET**

Kim Allyn, DVM

- Tracheal collapse
- Suspect mild right sided pleural effusion

**INTERPRETATION OF THE FINDINGS & FURTHER RECOMMENDATIONS**

**INVOICE**

59871

The appreciated tracheal collapse is a plausible cause for the described cough. Tracheoscopy/bronchoscopy can be used for further grading of the tracheal collapse and to rule in/out accompanying bronchial collapse.

**DATE**

8-22-23

Ultrasound guided tapping of the suspected scant amount of pleural effusion can be performed for further workup; it might present an incidental finding.



**PATIENT**

Remi Bott

**SPECIES**

Canine

**BREED**

Pomeranian

**SEX**

Male

**AGE**

3 Years, 2 Months

**INTERPRETED BY**

Sebastian Schaub, DVM  
Dr. med. vet. DipECVDI

**HOSPITAL NAME**

Elizabeth Animal  
Hospital

**REFERRING VET**

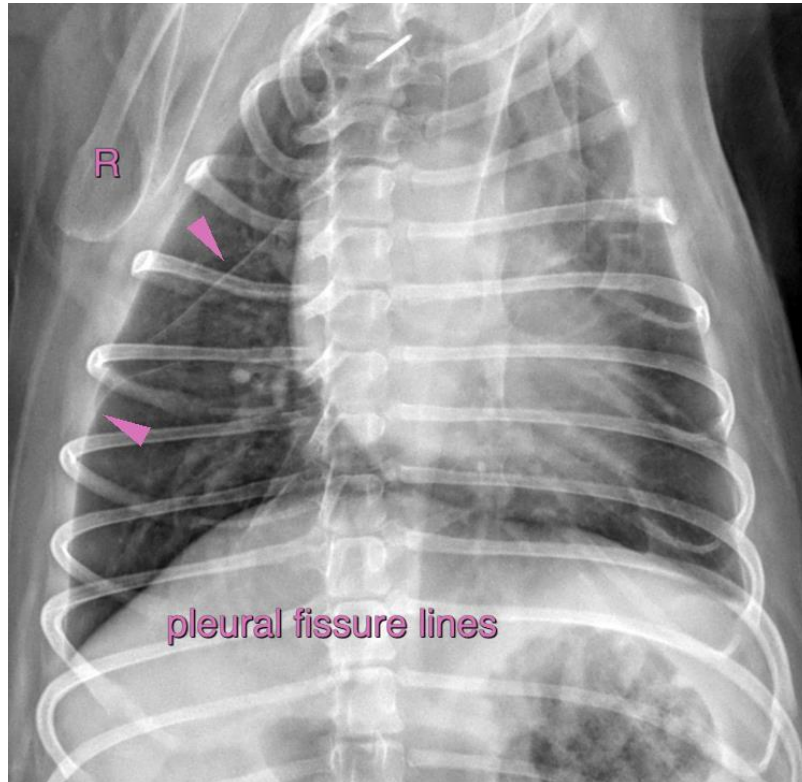
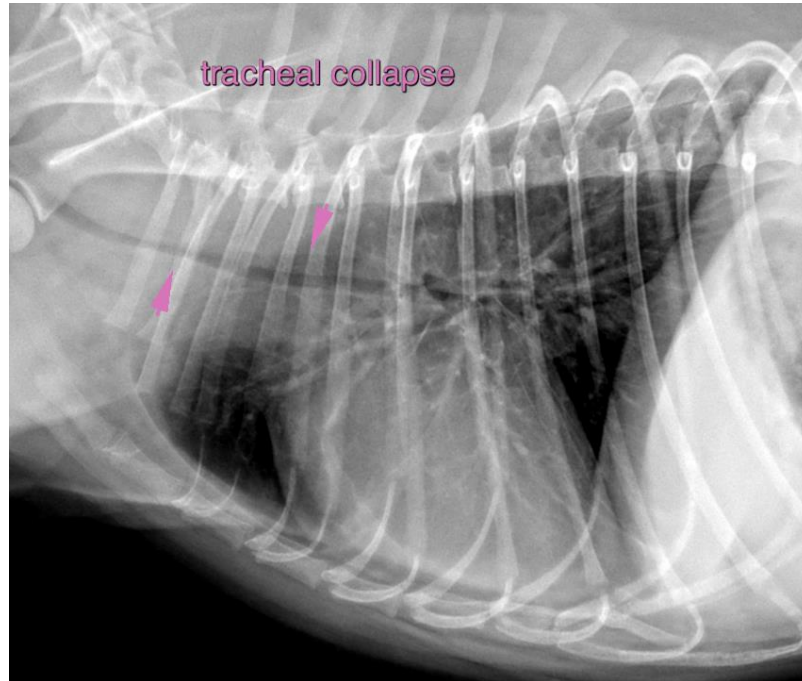
Kim Allyn, DVM

**INVOICE**

59871

**DATE**

8-22-23





**PATIENT**

Remi Bott **The information and recommendations provided are based on the images presented by the referring veterinarian/sonographer. No evaluation can be communicated regarding pathology that was not visible in the image/video clips provided.**

**SPECIES**

Canine

Thank you for this referral. If the clinical or image interpretation does not parallel your findings or if I can be of any further assistance please contact me.

**BREED**

Pomeranian

**Sebastian Schaub**, Sebastian Schaub, DVM, Dr. med. vet. DipECVDI  
[info@sonopath.com](mailto:info@sonopath.com)

**SEX**

Male

**AGE**

3 Years, 2 Months

**INTERPRETED BY**

Sebastian Schaub, DVM  
Dr. med. vet. DipECVDI

**HOSPITAL NAME**

Elizabeth Animal  
Hospital

**REFERRING VET**

Kim Allyn, DVM

**INVOICE**

59871

**DATE**

8-22-23