



PATIENT PRESENTING CLINICAL SIGNS

June July Widaman Bilateral TPLO sx in 2019 & 2021. P presented for limping on right hind leg since Sunday. Per O, P was chasing cat around the house and may have gotten injured then. P is still weight bearing, but O concerned about possible TPLO complication. Current medications: Thyro-Tabs, Denamarin, Antinol (Began yesterday)

SPECIES

Canine

Abnormal PE/Chem/CBC/UA Results: Musculoskeletal : Ambulatory x 4 with no obvious lameness, licks lips a little when R stifle is manipulated. BCS 6 / 9

RADIOGRAPHIC STUDY OF THE PELVIS AND STIFLE JOINTS

BREED

Radiographs of the pelvis and the stifle joints in two orthogonal imaging planes are provided for review.

Cattle Dog Mix

RADIOGRAPHIC FINDINGS

SEX

Female Spayed

The periarticular bones of the right coxofemoral joint present mild to moderate osteophyte new bone formation. The remainder of the osseous and surrounding soft tissue structures of the pelvis are within normal limits. The left coxofemoral joint presents smooth osseous margins and congruent joint space.

AGE

10 Years

A TPLO implant is seen at the medioproximal aspect of the tibia bilaterally; the osteotomy of the proximal tibia bilaterally is filled with trabecular bone. The TPLO implants are unremarkable in place. The periarticular bones of both stifle joints present mild to moderate osteophyte new bone formation. The right stifle joint presents a moderate intracapsular soft tissue swelling and the infrapatellar fat pad has a mild heterogeneity. The left stifle joint presents with a very mild intracapsular soft tissue swelling.

INTERPRETED BY

RADIOGRAPHIC DIAGNOSIS

Sebastian Schaub, DVM
Dr. med. vet. DipECVDI

- History of management of cranial cruciate ligament pathology both stifle joints via TPLO, the osteotomy bilaterally is in the remodeling phase
- Articular swelling right stifle joint
- Mild degenerative osteoarthritis stifle joints bilaterally
- Mild to moderate degenerative osteoarthritis right coxofemoral joint

HOSPITAL NAME

DTLAvets

INTERPRETATION OF THE FINDINGS & FURTHER RECOMMENDATIONS

REFERRING VET

Dr. Amini

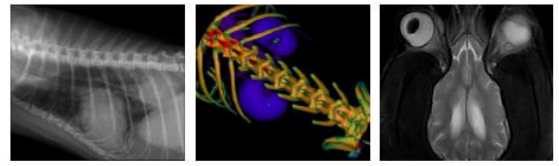
The joint effusion of the right stifle joint can be a sequela to preceding traumatic insult ± meniscal injury. Arthritis of the right stifle joint is a potential and a synovial tap can be performed for further definition. No radiographic abnormalities along the TPLO implants or underlying bone are appreciated.

INVOICE

59865

DATE

8-22-23



PATIENT

June July Widaman

SPECIES

Canine

BREED

Cattle Dog Mix

SEX

Female Spayed

AGE

10 Years

INTERPRETED BY

Sebastian Schaub, DVM
Dr. med. vet. DipECVDI

HOSPITAL NAME

DTLAvets

REFERRING VET

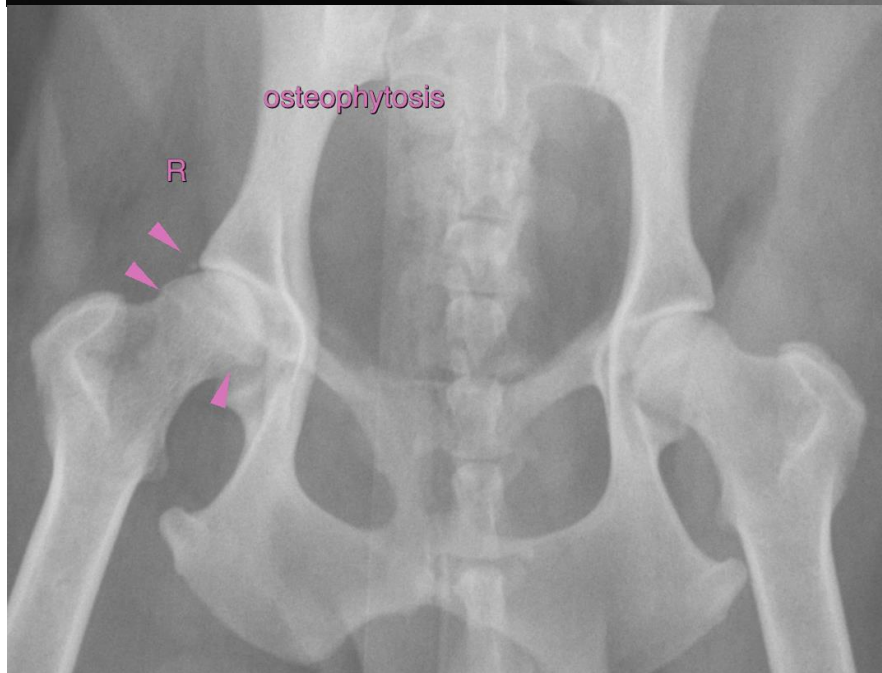
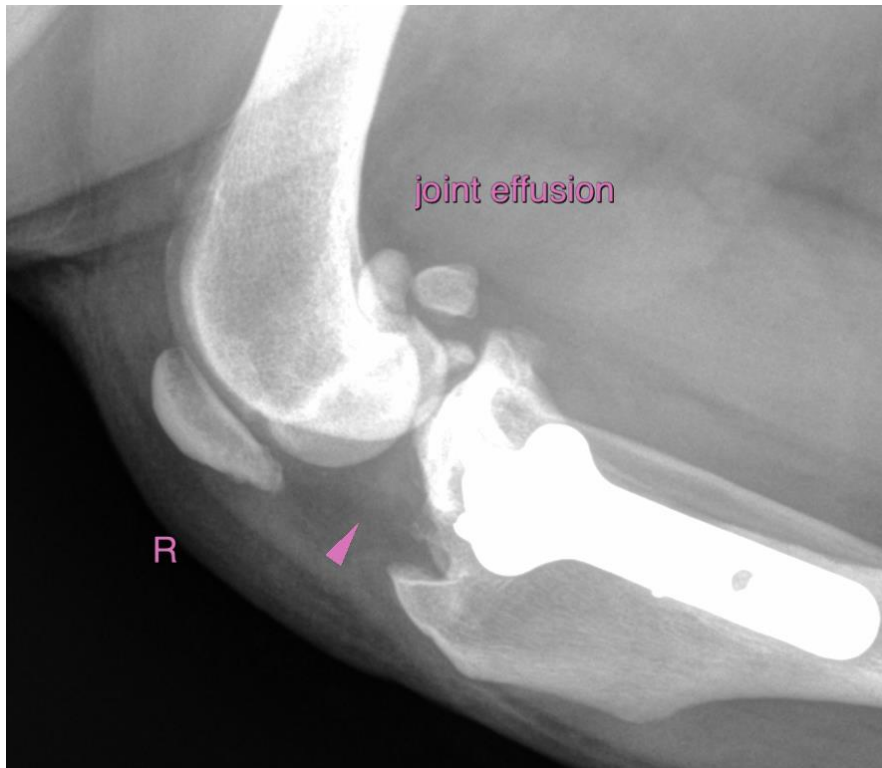Dr. Amini

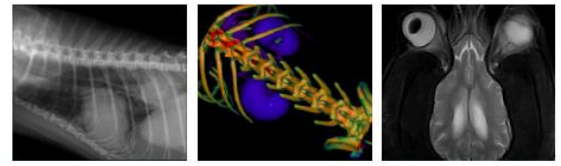
INVOICE

59865

DATE

8-22-23





PATIENT The information and recommendations provided are based on the images presented by the referring veterinarian/sonographer. No evaluation can be communicated regarding pathology that was not visible in the image/video clips provided.

June July Widaman

Thank you for this referral. If the clinical or image interpretation does not parallel your findings or if I can be of any further assistance please contact me.

SPECIES

Canine

Sebastian Schaub, Sebastian Schaub, DVM, Dr. med. vet. DipECVDI
info@sonopath.com

BREED

Cattle Dog Mix

SEX

Female Spayed

AGE

10 Years

INTERPRETED BY

Sebastian Schaub, DVM
Dr. med. vet. DipECVDI

HOSPITAL NAME

DTLAvets

REFERRING VET

Dr. Amini

INVOICE

59865

DATE

8-22-23