



PATIENT PRESENTING CLINICAL SIGNS

Bear Fonda limping on and off for a few weeks was left front for few weeks then on right front then hind legs - seemed unsteady for 1-2 days now limping on right front holding up doesn't cry when walking, cried out on palpation of distal humerus still playing and eating normally

SPECIES RADIOGRAPHIC STUDY OF THE SHOULDER & ELBOW JOINTS

Canine Radiographs of the right shoulder joint and the right & left elbow joint are provided for review.

RADIOGRAPHIC FINDINGS

BREED The growth plates are age related open.

German Shepherd The periarticular bones of the right shoulder joint has smooth osseous margins, unremarkable.

SEX The medullary cavity of the humeral diaphysis bilaterally and the proximal third of the diaphysis of the right radius & ulna present a significant patchy sclerosis. Along the caudal aspect of the diaphysis of the right humerus, solid, but ill-defined periosteal new bone formation is appreciated.

Male Both elbow joints have smooth osseous margins of the periarticular bones. The contour of the medial coronoid process of both elbow joints is well-defined and has a homogeneous density.

AGE RADIOGRAPHIC DIAGNOSIS

- 5 Months
- Panosteitis
 - Normal right shoulder joint
 - Normal elbow joints bilaterally

INTERPRETED BY

Sebastian Schaub, DVM
Dr. med. vet. DipECVDI

INTERPRETATION OF THE FINDINGS & FURTHER RECOMMENDATIONS

The radiographic study is consistent with panosteitis – being a plausible explanation for the presenting clinical signs.

HOSPITAL NAME

Hart Family
Veterinary Clinic

REFERRING VET

Dr. Soleil Gagne

INVOICE

59872

DATE

8-22-23



PATIENT

Bear Fonda

SPECIES

Canine

BREED

German Shepherd

SEX

Male

AGE

5 Months

INTERPRETED BY

Sebastian Schaub, DVM
Dr. med. vet. DipECVDI

HOSPITAL NAME

Hart Family
Veterinary Clinic

REFERRING VET

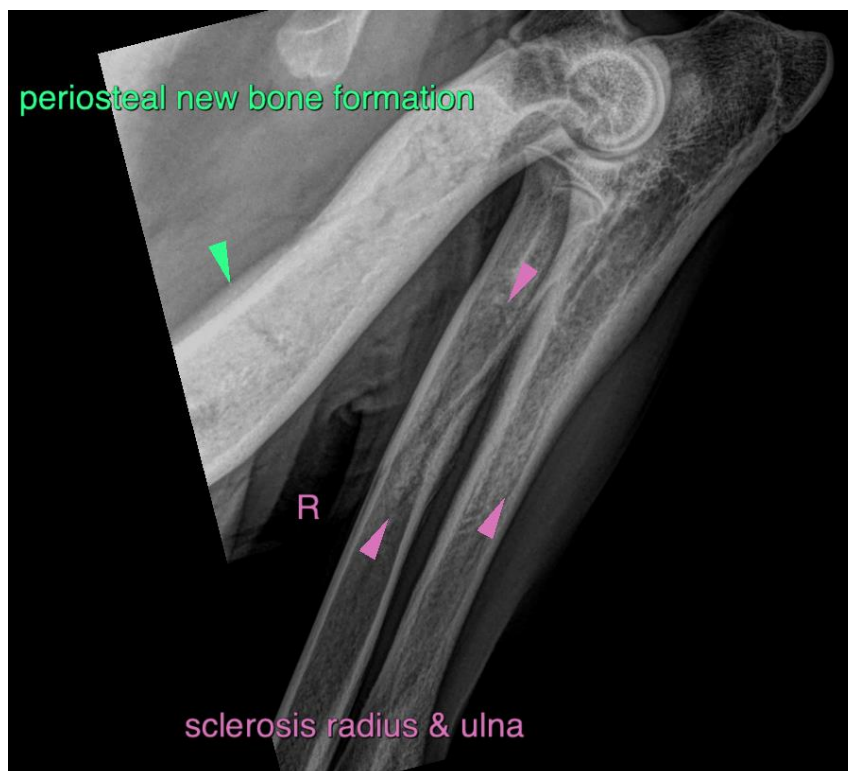
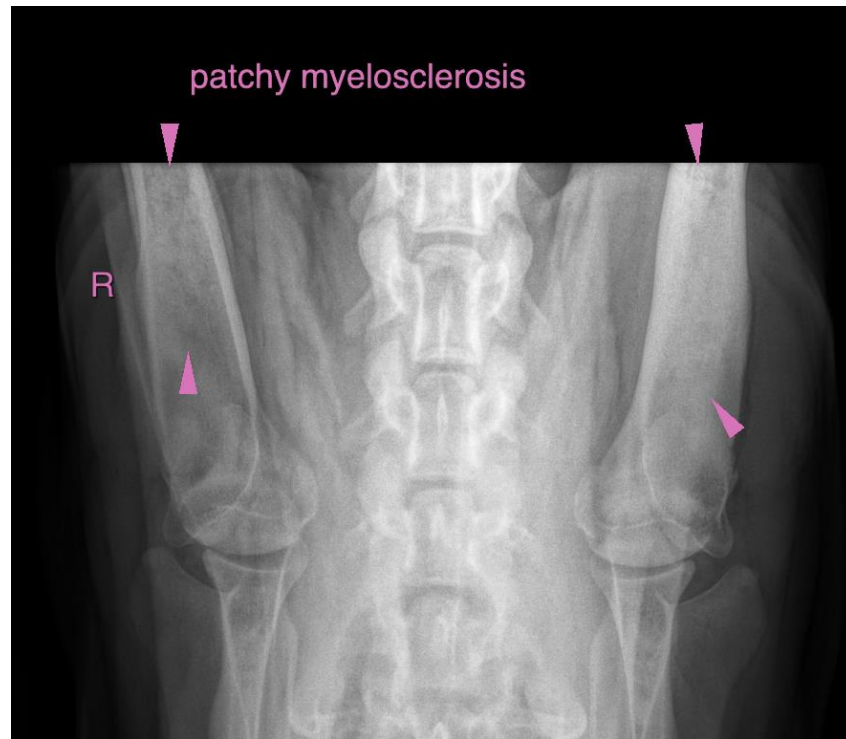
Dr. Soleil Gagne

INVOICE

59872

DATE

8-22-23





PATIENT

Bear Fonda

The information and recommendations provided are based on the images presented by the referring veterinarian/sonographer. No evaluation can be communicated regarding pathology that was not visible in the image/video clips provided.

SPECIES

Canine

Thank you for this referral. If the clinical or image interpretation does not parallel your findings or if I can be of any further assistance please contact me.

BREED

German Shepherd

Sebastian Schaub, Sebastian Schaub, DVM, Dr. med. vet. DipECVDI
info@sonopath.com

SEX

Male

AGE

5 Months

INTERPRETED BY

Sebastian Schaub, DVM
Dr. med. vet. DipECVDI

HOSPITAL NAME

Hart Family
Veterinary Clinic

REFERRING VET

Dr. Soleil Gagne

INVOICE

59872

DATE

8-22-23