



**PATIENT**

Lilly Newfer

**PRESENTING CLINICAL SIGNS**

Pet presented for a 2 month history of lameness affecting the left front limb. A 2 week trial of rest and NSAIDs provided minimal improvement and issues worsened with return to activity. Radiographs suggestive of degenerative changes in the left elbow

**SPECIES**

Canine

**COMPUTED TOMOGRAPHY OF THE FRONT LIMBS**

A high resolution pre- and post-contrast CT study of the front limbs is provided for review.

**BREED**

Pit Bull Terrier Mix

**COMPUTED TOMOGRAPHIC FINDINGS**

Both shoulder joints present smooth osseous margins and the surrounding soft tissue structures are within normal limits.

**SEX**

Female

The periarticular bones of both elbow joints present mild to moderate osteophyte new bone formation. The medial coronoid process of both elbow joints has an irregular conformation and presents a heterogeneous density with reduced attenuation pattern of the cranial tip. An ill-defined fissure line is seen caudal to the tip of the medial coronoid process of the left elbow joint. The joint space of both elbow joints is congruent.

**AGE**

2 Years

**COMPUTED TOMOGRAPHIC DIAGNOSIS**

- Coronoid disease elbow joints bilaterally
- Mild to moderate degenerative osteoarthritis elbow joints bilaterally
- Structural normal shoulder joints

**INTERPRETED BY**

Sebastian Schaub, DVM  
Dr. med. vet. DipECVDI

**INTERPRETATION OF THE FINDINGS & FURTHER RECOMMENDATIONS**

The findings are consistent with mild to moderate chronic degenerative joint disease of both elbow joints disease of the medial coronoid process – suspect non-vital tip.

**HOSPITAL NAME**

Wilson Veterinary  
Hospital

Arthroscopy/Arthrotomy is recommended to revise the elbow joints and remove potential non-vital bone of the medial coronoid process.

**REFERRING VET**

Dr. Burge

**INVOICE**

53627

**DATE**

8-22-22



**PATIENT**

Lilly Newfer

**SPECIES**

Canine

**BREED**

Pit Bull Terrier Mix

**SEX**

Female

**AGE**

2 Years

**INTERPRETED BY**

Sebastian Schaub, DVM  
Dr. med. vet. DipECVDI

**HOSPITAL NAME**

Wilson Veterinary  
Hospital

**REFERRING VET**

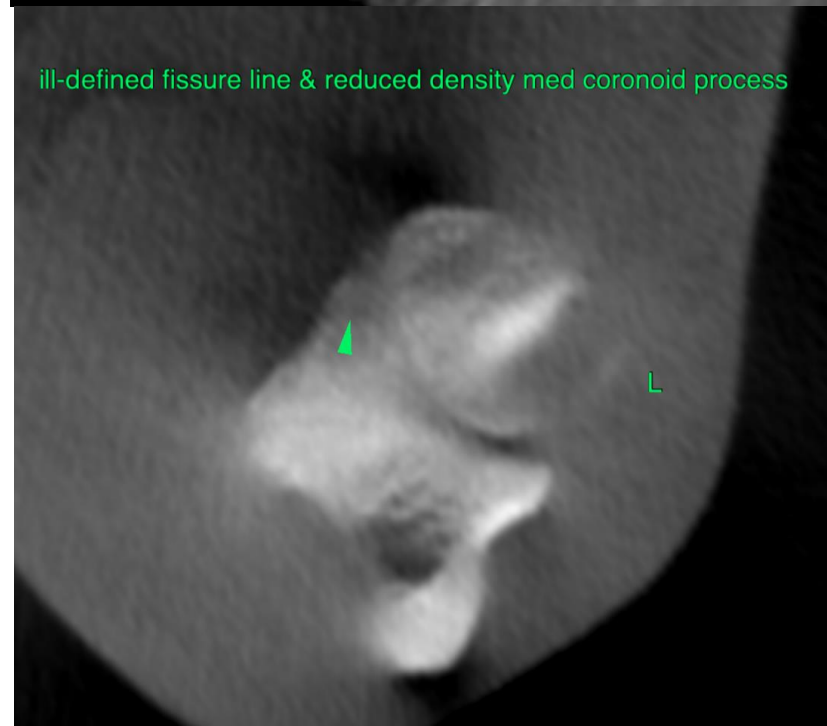
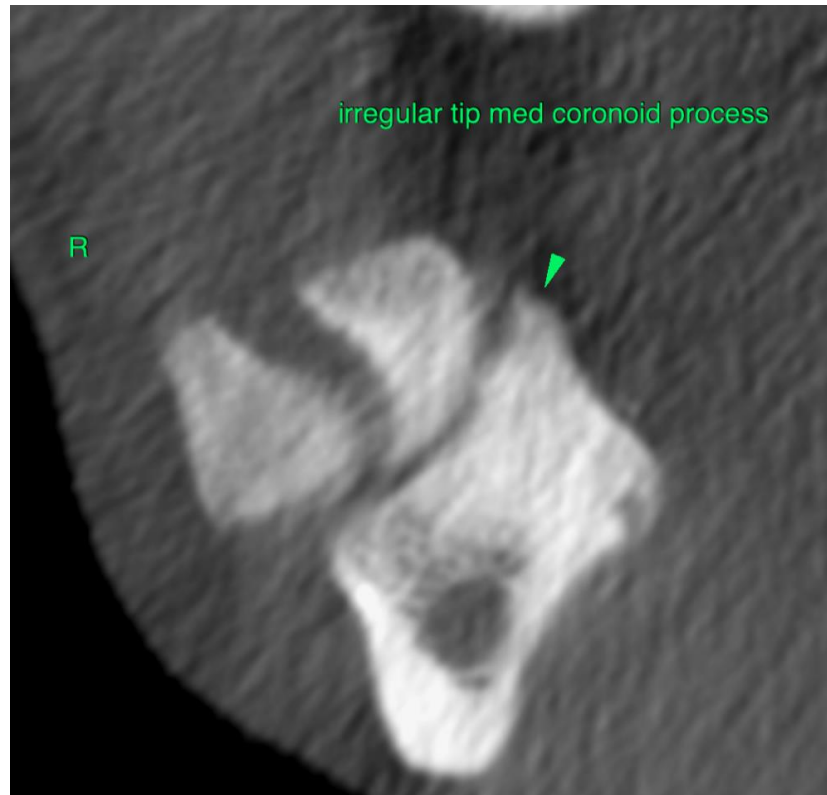Dr. Burge

**INVOICE**

53627

**DATE**

8-22-22





**PATIENT**

Lilly Newfer

**SPECIES**

Canine

The information and recommendations provided are based on the images presented by the referring veterinarian/sonographer. No evaluation can be communicated regarding pathology that was not visible in the image/video clips provided.

**BREED**

Pit Bull Terrier Mix

Thank you for this referral. If the clinical or image interpretation does not parallel your findings or if I can be of any further assistance please contact me.

**Sebastian Schaub**, Sebastian Schaub, DVM, Dr. med. vet. DipECVDI  
sebast.schaub@gmail.com

**SEX**

Female

**AGE**

2 Years

**INTERPRETED BY**

Sebastian Schaub, DVM  
Dr. med. vet. DipECVDI

**HOSPITAL NAME**

Wilson Veterinary  
Hospital

**REFERRING VET**

Dr. Burge

**INVOICE**

53627

**DATE**

8-22-22