



PATIENT PRESENTING CLINICAL SIGNS

Dublin McCoy Swelling of left eye, pain on left side of face/throat
 Abnormal PE/Chem/CBC/UA Results: Decreased retroplulsion OS, pain when opening mouth.
 Stab incision made behind 211 today for retrobulbar abscess

SPECIES COMPUTED TOMOGRAPHY OF THE SKULL

Canine A high resolution pre- and post-contrast CT study of the skull is provided for review.

BREED COMPUTED TOMOGRAPHIC FINDINGS

Terrier Mix The pictured parts of the dentition are complete and unremarkable in all jaw quadrants.

The nasal cavity presents the expected aerated spaces between thin & even conchae and turbinates with smooth mucosal lining.

SEX A mild swelling of the retrobulbar tissue in the left orbit is seen. Post contrast administration, in the rostroventral aspect of the left temporal muscle, a peripheral contrast enhancing and central hypoattenuating, fusiform shaped region is visible, measuring 10 x 5 x 5 mm in size. The left ocular bulb is mildly deviated rostrally and dorsally.

Female Spayed

AGE The left obliquus dorsalis muscle presents mild punctuate dystrophic mineralization.

7 Years, 2 Months Both temporomandibular joints present congruent joint spaces with even subchondral bone surfaces and are considered within normal limits.

INTERPRETED BY Both tympanic bullae are aerated, the mucosal lining is not seen, the bony wall is smooth and thin. The external ear canals are within normal limits.

Sebastian Schaub, DVM
 Dr. med. vet. DipECVDI

The brain presents no deviation from normal anatomy and symmetry. The brain parenchyma is homogeneous and within normal limits for attenuation and distribution of contrast enhancement. The ventricular system is non-dilated and symmetric.

HOSPITAL NAME The left medial retropharyngeal lymph node is prominent.

Catskill Veterinary Services, PLLC

COMPUTED TOMOGRAPHIC DIAGNOSIS

- Small cavitory lesion rostroventral aspect left temporal muscle
- Diffuse left sided retrobulbar swelling
- Secondary left sided exophthalmos
- Lymphadenopathy left medial retropharyngeal lymph node

REFERRING VET

Dr Sara Wright

INTERPRETATION OF THE FINDINGS & FURTHER RECOMMENDATIONS

INVOICE The CT study is consistent with retrobulbar abscess with small cavitory lesion in the rostroventral aspect of the left temporal muscle and secondary left sided retrobulbar cellulitis. An underlying cause for the abscess formation is not identified – suspect preceding puncture wound, a migrating isoattenuating foreign body is a potential as well. Stab incision has already been performed to drain the abscess.

53642

DATE

8-22-22

Secondary reactive hyperplasia of the left medial retropharyngeal lymph node.



PATIENT

Dublin McCoy

SPECIES

Canine

BREED

Terrier Mix

SEX

Female Spayed

AGE

7 Years, 2 Months

INTERPRETED BY

Sebastian Schaub, DVM
Dr. med. vet. DipECVDI

HOSPITAL NAME

Catskill Veterinary
Services, PLLC

REFERRING VET

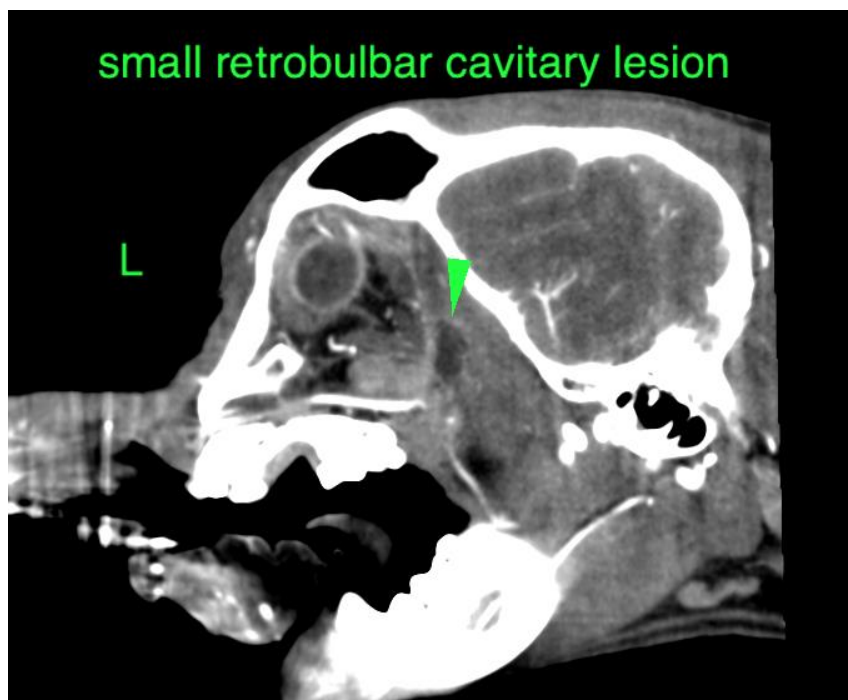
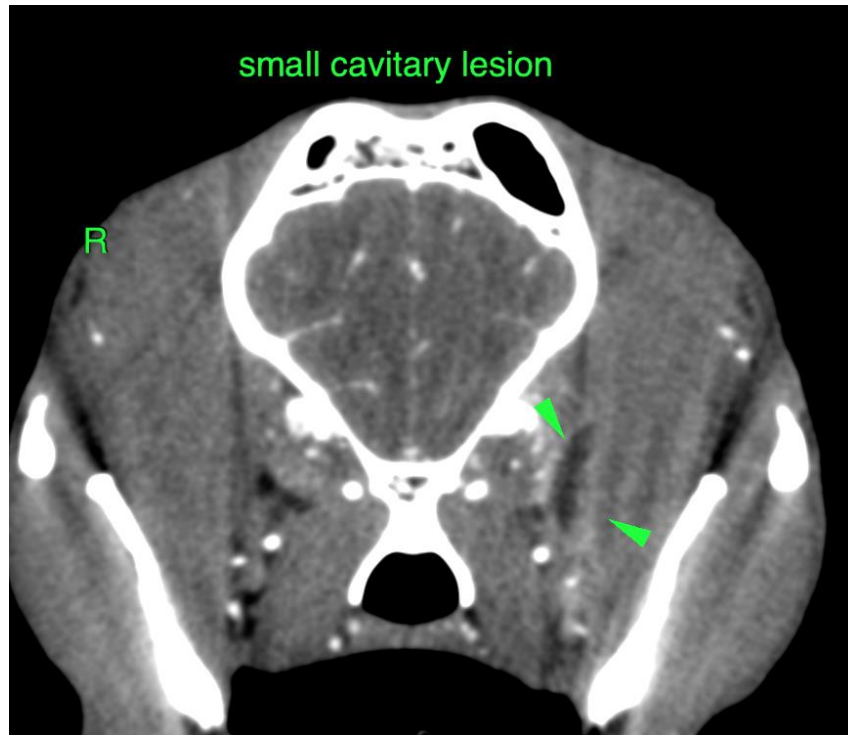
Dr Sara Wright

INVOICE

53642

DATE

8-22-22





PATIENT

Dublin McCoy

The information and recommendations provided are based on the images presented by the referring veterinarian/sonographer. No evaluation can be communicated regarding pathology that was not visible in the image/video clips provided.

SPECIES

Canine

Thank you for this referral. If the clinical or image interpretation does not parallel your findings or if I can be of any further assistance please contact me.

Sebastian Schaub, Sebastian Schaub, DVM, Dr. med. vet. DipECVDI
sebast.schaub@gmail.com

BREED

Terrier Mix

SEX

Female Spayed

AGE

7 Years, 2 Months

INTERPRETED BY

Sebastian Schaub, DVM
Dr. med. vet. DipECVDI

HOSPITAL NAME

Catskill Veterinary
Services, PLLC

REFERRING VET

Dr Sara Wright

INVOICE

53642

DATE

8-22-22