



PATIENT PRESENTING CLINICAL SIGNS

PATIENT King Sarley **PRESENTING CLINICAL SIGNS** History: 10 YR OLD NEUTERED CHIHUAHUA PRESENTED TODAY FOR STRAINING TO DEFECATE. PET HAS A DECREASED APPETITE AND IS ANXIOUS/AGGRESSIVE.

SPECIES Abnormal PE/Chem/CBC/UA Results: Hydration: Appropriately hydrated Mentation: BAR EENT: No nasal discharge; nuclear sclerosis OU; clean no exudate AU; No cough on tracheal palpation. Oral Cavity: muzzled Lymph Nodes: Symmetrical, no changes in size, shape, consistency Skin: Good hair coat, no signs of ectoparasites. No lesions noted. CV/Respiratory: No murmur/arrhythmia or crackles/wheezing auscultated. Synchronous pulses, normal rate. Normal bronchovesicular sounds.
BREED Canine
BREED Chihuahua
 Abd/GI: Soft non painful abdomen, no organomegaly, no abnormalities on abdominal palpation Uro/Perineum: Rectal- large fecal ball in rectum, could not break up with finger or pull out, blood on glove Musculoskeletal: Normal ambulation, no lameness noted. BCS 6/9 Neurological: Appropriate

RADIOGRAPHIC STUDY OF THE ABDOMEN

SEX Neutered Male
 A full set of radiographs of the abdomen is provided for review.

RADIOGRAPHIC FINDINGS

AGE 10 Years
 Generalized moderate spondylosis formation is seen along the lumbar spine. The intervertebral disc space L2/L3 is collapsed and the intervertebral disc spaces L4/L5 and L5/L6 are moderately narrowed.

INTERPRETED BY

Sebastian Schaub,
 DVM Dr. med. vet.
 DipECVDI

No abnormalities of the extraabdominal soft tissues are noted. The abdominal wall is smooth and thin.
 The serosal detail is maintained throughout the peritoneal and retroperitoneal space.

HOSPITAL NAME

DPC Veterinary H

The liver is appropriate in position, size and presents uniform opacity.
 The splenic head is in the anticipated position and within normal limits for size and opacity. The splenic body and tail are considered normal for position, size, shape and opacity.

REFERRING VET

Dr. White

Both kidneys are seen and present with normal size, shape, delineation and opacity. The urinary bladder is empty and cannot clearly appreciated. No radiopaque calculi are noted throughout the upper and lower urinary tract.

INVOICE

12672

The stomach is in its anticipated position and presents normal content.
 The small intestinal loops are of even diameter and non-dilated, a small amount of gas is seen within the small intestinal loops and considered within normal limits.

DATE

8/22/21

RADIOGRAPHIC DIAGNOSIS

The colon is seen in the expected position. The rectum is moderately distended by fecal material, accentuated in the left aspect. The base of the tail is mildly displaced dorsally.



PATIENT

King Sarley

- Possible left sided rectal ectasia
- Empty urinary bladder
- Chronic discopathy L2/L3, L4/L5 and L5/L6
- Spondylosis deformans

SPECIES

Canine

INTERPRETATION OF THE FINDINGS & FURTHER RECOMMENDATIONS

BREED

Chihuahua

The findings are concerning for perineal hernia with secondary rectal ectasia and constipation. Although constipation due to dried in fecal material in the rectum is a potential as well. If not done so yet, a rectal exam is mandatory to rule in/out perineal hernia or stricture.

SEX

Neutered Male

The urinary bladder is empty and cannot be appreciated, in case of perineal hernia there is chance for caudal herniation of the prostate and/or urinary bladder with secondary dysuria.

AGE

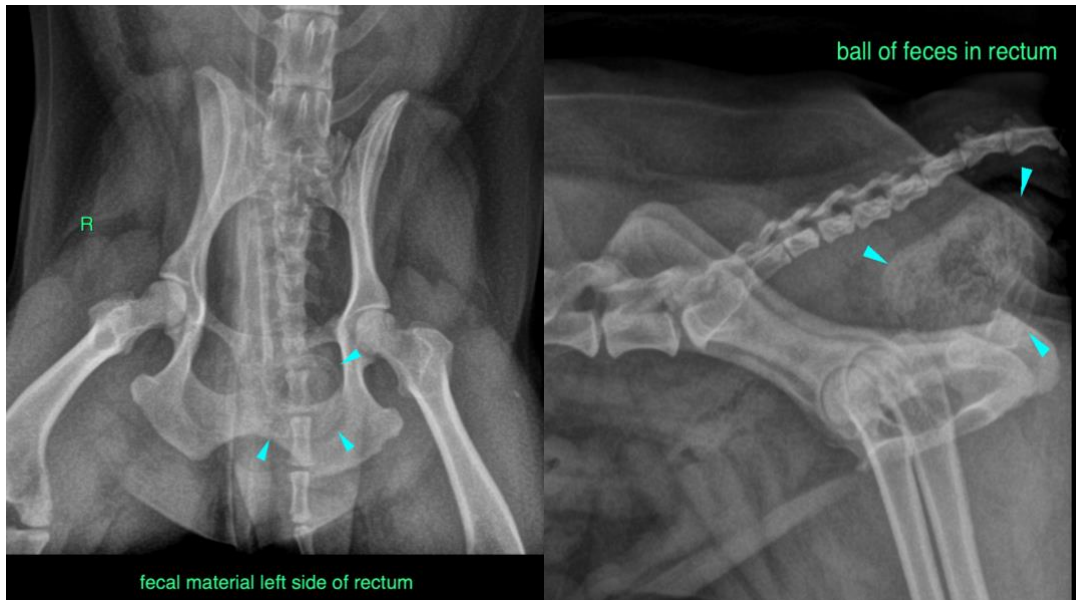
10 Years

INTERPRETED BY

Sebastian Schaub,
DVM Dr. med. vet.
DipECVDI

HOSPITAL NAME

DPC Veterinary H



REFERRING VET

Dr. White

The information and recommendations provided are based on the images presented by the referring veterinarian. No evaluation can be communicated regarding pathology that was not visible in the image/video clips provided.

Thank you for this referral. If the clinical or image interpretation does not parallel your findings or if I can be of any further assistance please contact me.

INVOICE

12672

Sebastian Schaub, Sebastian Schaub, DVM, Dr. med. vet. DipECVDI
sebast.schaub@gmail.com

DATE

8/22/21



PATIENT

King Sarley

SPECIES

Canine

BREED

Chihuahua

SEX

Neutered Male

AGE

10 Years

INTERPRETED BY

Sebastian Schaub,
DVM Dr. med. vet.
DipECVDI

HOSPITAL NAME

DPC Veterinary H

REFERRING VET

Dr. White

INVOICE

12672

DATE

8/22/21