



PATIENT PRESENTING CLINICAL SIGNS

Webster Desormeaux Limping on right front for about a month. Did better with rest then returned.
Abnormal PE/Chem/CBC/UA Results: Decreased range of motion with poor conformation both elbows; crepitus (crunching) of both stifles (knees) with flexion Heavy.

SPECIES RADIOGRAPHIC STUDY OF THE ELBOW JOINTS

Canine Radiographs of the elbow joints in two orthogonal imaging planes are provided for review.

RADIOGRAPHIC FINDINGS

BREED The periarticular bones of both elbow joints present moderate to marked osteophyte new bone formation. The contour of the medial coronoid process is ill-defined and the tip cannot be delineated.

Staffordshire Terrier

RADIOGRAPHIC DIAGNOSIS

- SEX
- Coronoid disease elbow joints bilaterally
 - Advanced degenerative osteoarthritis elbow joints bilaterally

Neutered

INTERPRETATION OF THE FINDINGS & FURTHER RECOMMENDATIONS

AGE The radiographic changes of both elbow joints are consistent with advanced degenerative joint disease due to underlying coronoid disease. The changes are a plausible cause for the front limb lameness.

5 Years, 9 Months

INTERPRETED BY

Sebastian Schaub, DVM
Dr. med. vet. DipECVDI

HOSPITAL NAME

Elizabeth Animal
Hospital

REFERRING VET

Jennifer Redus, DVM

INVOICE

59839

DATE

8-21-23



PATIENT

Webster Desormeaux

SPECIES

Canine

BREED

Staffordshire Terrier

SEX

Neutered

AGE

5 Years, 9 Months

INTERPRETED BY

Sebastian Schaub, DVM
Dr. med. vet. DipECVDI

HOSPITAL NAME

Elizabeth Animal
Hospital

REFERRING VET

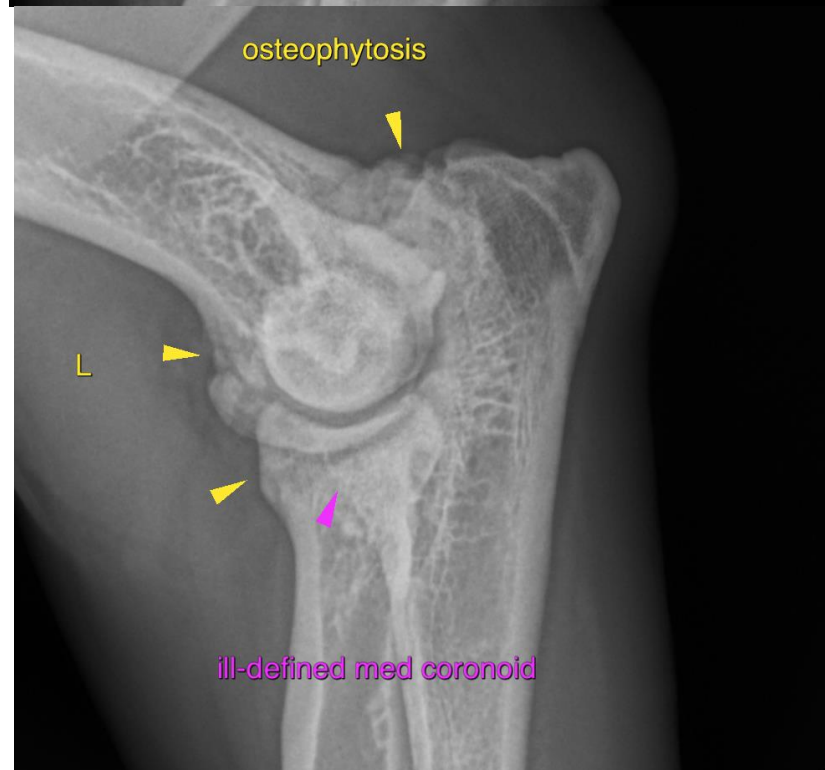
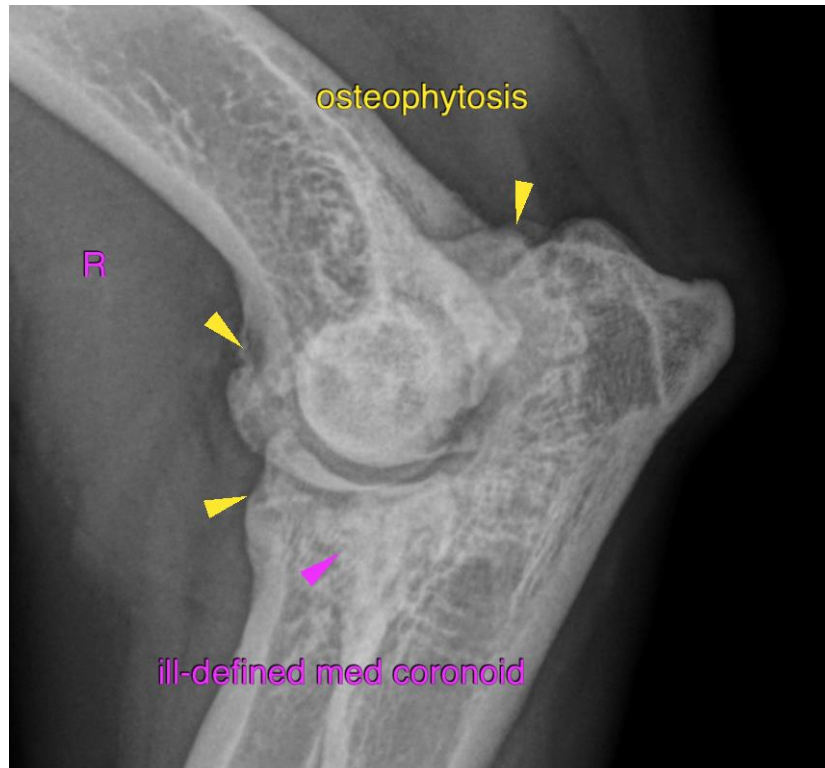
Jennifer Redus, DVM

INVOICE

59839

DATE

8-21-23





PATIENT

Webster Desormeaux

The information and recommendations provided are based on the images presented by the referring veterinarian/sonographer. No evaluation can be communicated regarding pathology that was not visible in the image/video clips provided.

SPECIES

Canine

Thank you for this referral. If the clinical or image interpretation does not parallel your findings or if I can be of any further assistance please contact me.

BREED

Staffordshire Terrier

Sebastian Schaub, Sebastian Schaub, DVM, Dr. med. vet. DipECVDI
info@sonopath.com

SEX

Neutered

AGE

5 Years, 9 Months

INTERPRETED BY

Sebastian Schaub, DVM
Dr. med. vet. DipECVDI

HOSPITAL NAME

Elizabeth Animal
Hospital

REFERRING VET

Jennifer Redus, DVM

INVOICE

59839

DATE

8-21-23