



PATIENT PRESENTING CLINICAL SIGNS

Iron Fernandez History of acute onset paresis(Saturday 5pm). Non ambulatory, Deep Pain present. Suspect IVDD TL area.
Abnormal PE/Chem/CBC/UA Results: CBC -- unremarkable CHEM --- unremarkable

SPECIES COMPUTED TOMOGRAPHY OF THE THORACIC & LUMBAR SPINE

Canine A high resolution pre- and post-contrast CT study of the skull and abdomen and a post-contrast CT study of the thorax are provided for review.

BREED COMPUTED TOMOGRAPHIC FINDINGS

Dachshund THE LAST RIB BEARING VERTEBRA IS COUNTED AS T13.

The intervertebral disc space T11/T12 is narrowed and a vacuum phenomenon is appreciated in the respective intervertebral disc space. Level with the intervertebral disc space T11/T12, mild hyperattenuating material is appreciated in the vertebral canal, occupying approximately 40% of the cross-sectional area of the vertebral canal at the same level – extending cranially up to the level of the mid third of the vertebral body of T11 cranially and caudally up to the level of the caudal vertebral endplate of T12. The dural tube is surrounded by a thin rim of hyperattenuating material extending up to the level of T7 cranially and up to the caudal vertebral endplate of T12.

AGE Multiple intervertebral discs along the thoracic and lumbar spine present mild central mineralization.

3 Years **COMPUTED TOMOGRAPHIC DIAGNOSIS**

INTERPRETED BY

- Left sided intervertebral disc extrusion T11/T12 with likely secondary epidural hemorrhage
- Multifocal chondroid disc degeneration

Sebastian Schaub, DVM
Dr. med. vet. DipECVDI

INTERPRETATION OF THE FINDINGS & FURTHER RECOMMENDATIONS

HOSPITAL NAME The intervertebral disc extrusion T11/T12 is a plausible explanation for the presenting clinical signs and surgical decompression via a left approach to the vertebral canal is considered as the therapy of choice.
Veterinary Image Center

REFERRING VET

Dr. J. Colon, DVM

INVOICE

59820

DATE

8-21-23



PATIENT

Iron Fernandez

SPECIES

Canine

BREED

Dachshund

SEX

NM

AGE

3 Years

INTERPRETED BY

Sebastian Schaub, DVM
Dr. med. vet. DipECVDI

HOSPITAL NAME

Veterinary Image
Center

REFERRING VET

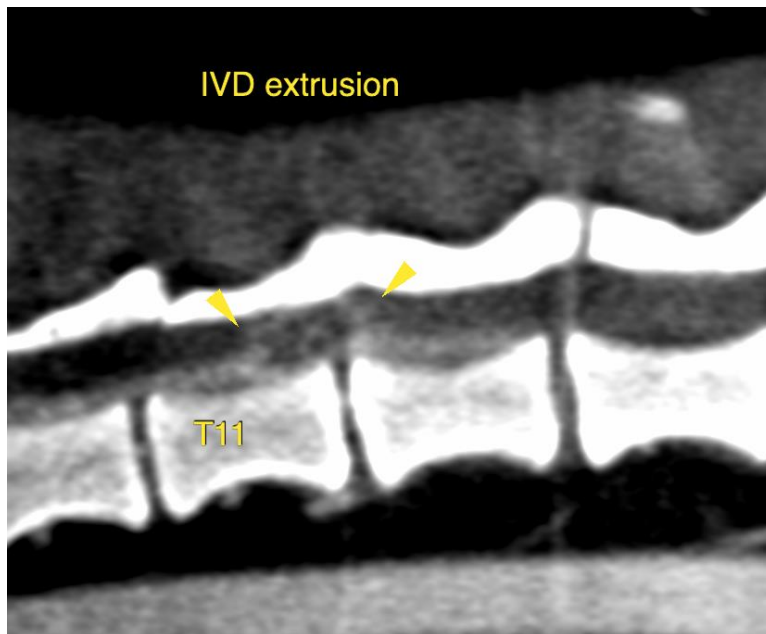
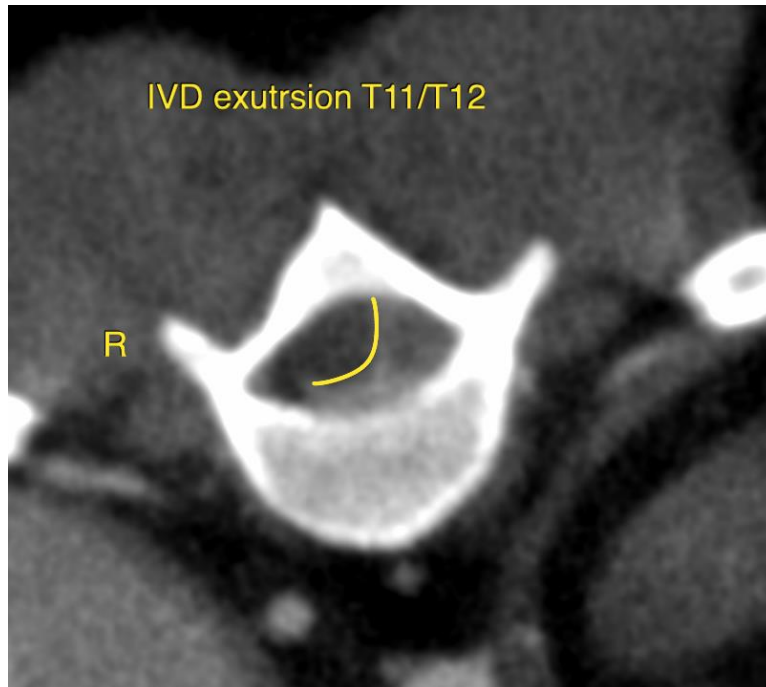
Dr. J. Colon, DVM

INVOICE

59820

DATE

8-21-23





PATIENT

Iron Fernandez

The information and recommendations provided are based on the images presented by the referring veterinarian/sonographer. No evaluation can be communicated regarding pathology that was not visible in the image/video clips provided.

Thank you for this referral. If the clinical or image interpretation does not parallel your findings or if I can be of any further assistance please contact me.

SPECIES

Canine

Sebastian Schaub, Sebastian Schaub, DVM, Dr. med. vet. DipECVDI
info@sonopath.com

BREED

Dachshund

SEX

NM

AGE

3 Years

INTERPRETED BY

Sebastian Schaub, DVM
Dr. med. vet. DipECVDI

HOSPITAL NAME

Veterinary Image
Center

REFERRING VET

Dr. J. Colon, DVM

INVOICE

59820

DATE

8-21-23