

**PATIENT PRESENTING CLINICAL SIGNS**

Chase Edge 7 month old Shepherd that started limping at 3.5 months on and off. Treating lameness with Metacam and seems to be helping. History of -Umbilical Hernia -Ununited Anconeal Process of the right elbow  
Abnormal PE/Chem/CBC/UA Results: WNL

**SPECIES COMPUTED TOMOGRAPHY OF THE ELBOW JOINTS**

Canine A high resolution plain CT study of the elbow joints is provided for review.

**COMPUTED TOMOGRAPHIC FINDINGS****BREED**

German Shepherd

The anconeal process of the right elbow joint is separated from the ulna with an irregular marginated soft tissue filled gap. The periarticular bones of the right elbow joint present moderate osteophyte new bone formation. The medial coronoid process of the right elbow joint has a heterogeneous density and at the craniomedial aspect, three isolated, irregular shaped, osseous fragments, measuring up to 2.9 mm are appreciated. The joint space of the right elbow joint is incongruent.

**SEX**

Mi

The periarticular bones of the left elbow joint are smooth and the medial coronoid process has a homogeneous density and is well-defined.

**COMPUTED TOMOGRAPHIC DIAGNOSIS****AGE**

8 Months

- Fragmented medial coronoid process (FCP) right elbow joint
- Ununited anconeal process (UAP) right elbow joint
- Degenerative osteoarthritis right elbow joint
- Normal left elbow joint

**INTERPRETED BY**

Sebastian Schaub, DVM  
Dr. med. vet. DipECVDI

**INTERPRETATION OF THE FINDINGS & FURTHER RECOMMENDATIONS**

The degenerative joint disease of the right elbow joint is a sequela to FCP and UAP and the findings are a plausible explanation for right front limb lameness. Arthroscopy/arthrotomy is recommended to revise the right elbow joint and remove the loose osseous fragments to prevent further damage.

**HOSPITAL NAME**

Bridgwater  
Veterinary Hospital  
and Wellness Centre

**REFERRING VET**

Dr. Carley Lodge

**INVOICE**

59837

**DATE**

8-21-23



**PATIENT**

Chase Edge

**SPECIES**

Canine

**BREED**

German Shepherd

**SEX**

Mi

**AGE**

8 Months

**INTERPRETED BY**

Sebastian Schaub, DVM  
Dr. med. vet. DipECVDI

**HOSPITAL NAME**

Bridgwater  
Veterinary Hospital  
and Wellness Centre

**REFERRING VET**

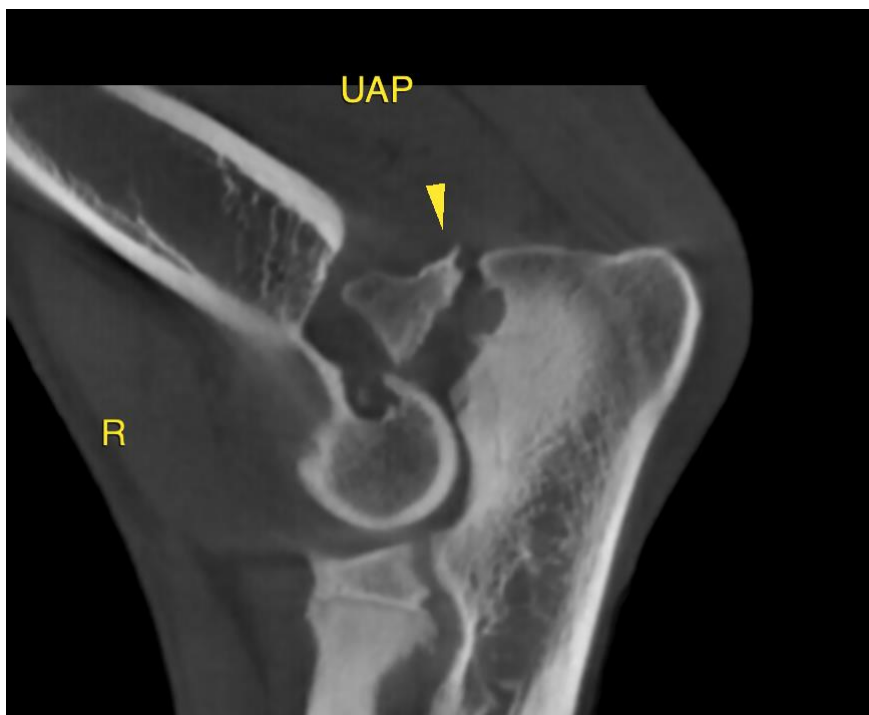
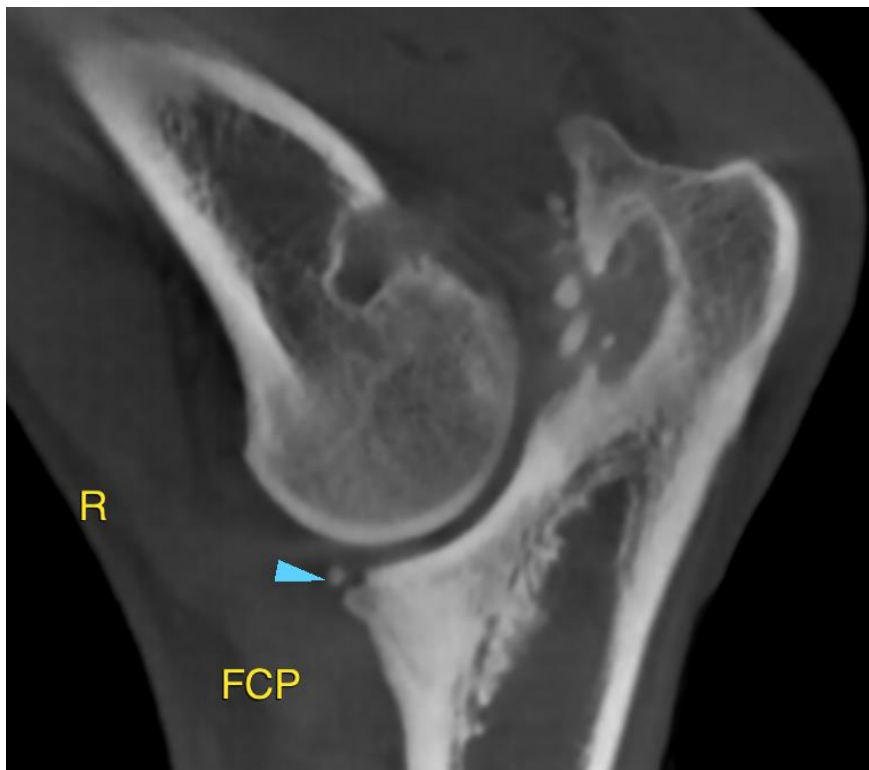
Dr. Carley Lodge

**INVOICE**

59837

**DATE**

8-21-23





**PATIENT**

Chase Edge

The information and recommendations provided are based on the images presented by the referring veterinarian/sonographer. No evaluation can be communicated regarding pathology that was not visible in the image/video clips provided.

**SPECIES**

Canine

Thank you for this referral. If the clinical or image interpretation does not parallel your findings or if I can be of any further assistance please contact me.

**Sebastian Schaub**, Sebastian Schaub, DVM, Dr. med. vet. DipECVDI  
[info@sonopath.com](mailto:info@sonopath.com)

**BREED**

German Shepherd

**SEX**

Mi

**AGE**

8 Months

**INTERPRETED BY**

Sebastian Schaub, DVM  
Dr. med. vet. DipECVDI

**HOSPITAL NAME**

Bridgwater  
Veterinary Hospital  
and Wellness Centre

**REFERRING VET**

Dr. Carley Lodge

**INVOICE**

59837

**DATE**

8-21-23