



PATIENT PRESENTING CLINICAL SIGNS

Bobby LaRussa Vomiting for days, decreased appetite, R/O F.B.

RADIOGRAPHIC STUDY OF THE ABDOMEN

SPECIES Radiographs of the abdomen in two orthogonal imaging planes are provided for review.

Canine **RADIOGRAPHIC FINDINGS**

The vertebral endplates T11/T12 present mild spondylosis formation.

BREED No abnormalities of the extraabdominal soft tissues are noted. The abdominal wall is smooth and thin.

Mixed The serosal detail is maintained throughout the peritoneal and retroperitoneal space.

The liver is appropriate in position, size and presents uniform opacity.

SEX The splenic head is in the anticipated position and within normal limits for size and opacity. The splenic body and tail are considered normal for position, size, shape and opacity.

Male Neutered

Both kidneys are seen and present with normal size, shape, delineation and opacity. The urinary bladder is in its anticipated position. No radiopaque calculi are noted throughout the upper and lower urinary tract.

AGE

5 Years The stomach is in its anticipated position and empty.

INTERPRETED BY

The small intestinal loops are of even diameter and non-dilated, a small amount of gas is seen within the small intestinal loops and considered within normal limits.

Sebastian Schaub, DVM
Dr. med. vet. DipECVDI

The colon is seen in the expected position and distended by gas.

RADIOGRAPHIC DIAGNOSIS

HOSPITAL NAME

- Empty gastrointestinal tract

Summit Dog & Cat
Hospital

INTERPRETATION OF THE FINDINGS & FURTHER RECOMMENDATIONS

REFERRING VET

Chan

The radiographic changes are most consistent with gastroenteritis - e.g. due to dietary indiscretion, parasitic infection, dysbacteriosis, pancreatitis. There is no evidence of radiopaque foreign material, abnormal gas pattern or signs for gastrointestinal mechanical obstruction. If clinical signs are refractory to therapy, recommend follow up radiographs or a complete abdominal ultrasound examination; in some cases a high ileus may lack classical radiographic signs of mechanical obstruction.

INVOICE

59817

DATE

8-21-23



PATIENT

Bobby LaRussa

SPECIES

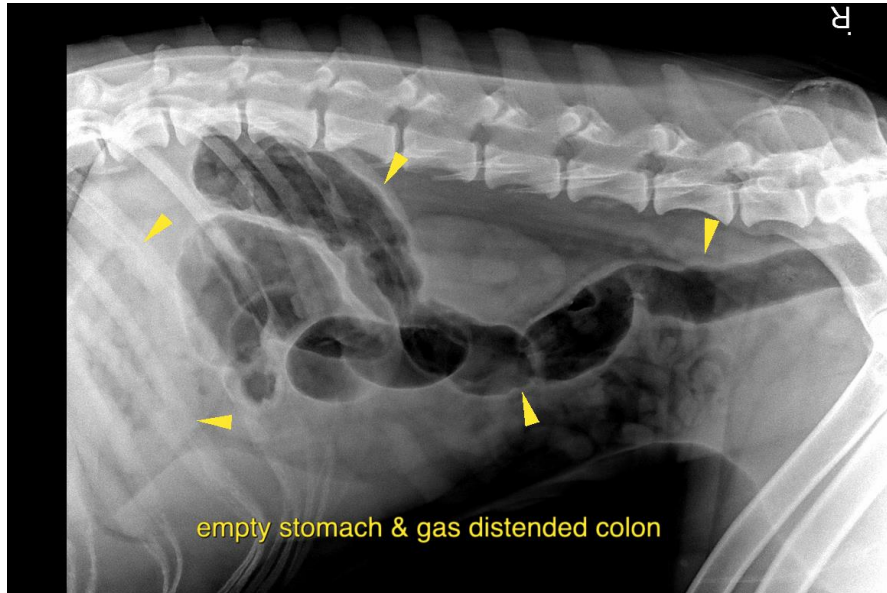
Canine

BREED

Mixed

SEX

Male Neutered



AGE

5 Years

INTERPRETED BY

Sebastian Schaub, DVM
Dr. med. vet. DipECVDI

The information and recommendations provided are based on the images presented by the referring veterinarian/sonographer. No evaluation can be communicated regarding pathology that was not visible in the image/video clips provided.

Thank you for this referral. If the clinical or image interpretation does not parallel your findings or if I can be of any further assistance please contact me.

HOSPITAL NAME

Summit Dog & Cat
Hospital

Sebastian Schaub, Sebastian Schaub, DVM, Dr. med. vet. DipECVDI
info@sonopath.com

REFERRING VET

Chan

INVOICE

59817

DATE

8-21-23