



PATIENT PRESENTING CLINICAL SIGNS

Roo Cricenti History: Limping on left hind leg and off started 3-4 months ago, worse in then last few day. No V/D/C Eating well. Very painful while manipulating the left knee to check the cranial drawer signs(possible positive for cranial drawer signs).

SPECIES

Canine Abnormal PE/Chem/CBC/UA Results: Blood work unremarkable / normal. 4DX done in another clinic and was negative.

BREED

Australian Shepherd Mix

RADIOGRAPHIC STUDY OF THE ABDOMEN, PELVIS AND STIFLE JOINTS

A complete set of radiographs of the abdomen, pelvis and stifle joints is provided for review.

RADIOGRAPHIC FINDINGS

SEX

Spayed Female

Abdomen:

The surrounding bony structures are within normal limits.

No abnormalities of the extraabdominal soft tissues are noted. The abdominal wall is smooth and thin.

AGE

8 Years

The serosal detail is maintained throughout the peritoneal and retroperitoneal space. A metal opaque surgical clip is seen in the region of the ovaries and cervix – history of spaying.

The liver is appropriate in position, size and presents uniform opacity.

INTERPRETED BY

Sebastian Schaub, DVM Dr. med. vet. DipECVDI

The splenic head is in the anticipated position and within normal limits for size and opacity. The splenic body and tail are considered normal for position, size, shape and opacity.

Both kidneys are seen and present with normal size, shape, delineation and opacity. The urinary bladder is in its anticipated position. No radiopaque calculi are noted throughout the upper and lower urinary tract.

HOSPITAL NAME

St. Catharine's AH

The stomach is in its anticipated position and presents normal content.

REFERRING VET

Dr. Bekhit

The small intestinal loops are of even diameter and non-dilated, a small amount of gas is seen within the small intestinal loops and considered within normal limits.

The colon is seen in the expected position and presents with appropriate content.

INVOICE

12664

Pelvis & Hind Limbs:

The osseous and surrounding soft tissue structures – including the coxofemoral joints – of the pelvis are within normal limits.

DATE

8/21/21



PATIENT The volume of the soft tissue shadow of the left hind limb is moderately decreased.

Roo Cricenti The left stifle joint presents mild osteophyte formation at the distal aspect of the patella. A mild intracapsular soft tissue swelling is noted.

SPECIES The right hind limb is within normal limits.

Canine

RADIOGRAPHIC DIAGNOSIS

- Mild articular swelling left stifle joint
- Mild degenerative osteoarthritis left stifle joint
- Moderate disuse atrophy left hind limb
- Structural normal abdomen

BREED

Australian Shepherd Mix

INTERPRETATION OF THE FINDINGS & FURTHER RECOMMENDATIONS

SEX The findings of the left stifle joint present evidence of mild joint effusion and early stage of degenerative osteoarthritis. The findings in conjunction with the given clinical signs are concerning for (partial) rupture of the cranial cruciate ligament with or without meniscal disease. However, as the degenerative changes are only mild despite the chronicity of clinical signs diagnosis has to be confirmed by a positive drawer sign or tibial compression test under general anesthesia. Rule out pathology originating from the spine/sciatic nerve as source for the clinical signs as well.

Spayed Female

AGE

8 Years

INTERPRETED BY

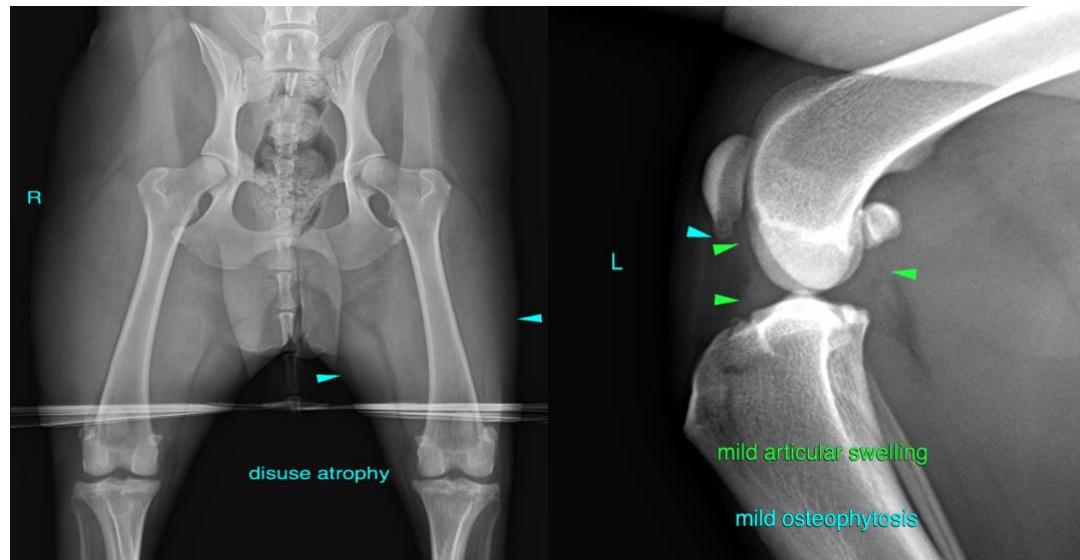
Sebastian Schaub,
DVM Dr. med. vet.
DipECVDI

HOSPITAL NAME

St. Catharine's AH

REFERRING VET

Dr. Bekhit



INVOICE

12664

The information and recommendations provided are based on the images presented by the referring veterinarian. No evaluation can be communicated regarding pathology that was not visible in the image/video clips provided.

DATE

8/21/21



PATIENT Thank you for this referral. If the clinical or image interpretation does not parallel your findings or if I can be of any further assistance please contact me.

Roo Cricenti

Sebastian Schaub, Sebastian Schaub, DVM, Dr. med. vet. DipECVDI
sebast.schaub@gmail.com

SPECIES

Canine

BREED

Australian Shepherd
Mix

SEX

Spayed Female

AGE

8 Years

INTERPRETED BY

Sebastian Schaub,
DVM Dr. med. vet.
DipECVDI

HOSPITAL NAME

St. Catharine's AH

REFERRING VET

Dr. Bekhit

INVOICE

12664

DATE

8/21/21