



**PATIENT PRESENTING CLINICAL SIGNS**

**Lola McQuay**  
**SPECIES** Canine  
**BREED** Rottweiler  
 History 3-month-old puppy. Found dragging of LHL peracutely after a yelp was heard in the middle of playing with her littermate. Progressed the next day, when RHL was also noted abnormal and she was non-ambulatory. Slightly improvement in RHL movement the following days while no improvement was noted in LHL On presentation to AHP Neuro on Aug 20th: non-ambulatory paraparesis with a posture of right-concaved scoliosis and mild voluntary movement in LHL. LHL deep pain present. Absent LHL postural reaction with intact spinal reflexes in HLs bilaterally. Absent cutaneous trunci reflex when left side was stimulated. Neurolocalization: T3-L3 myelopathy with left lateralizing Diagnostics CBC, chem - Aug 20th - overall unremarkable MRI (T-L spine) +CSF - Aug 20th \*\*

**MAGNETIC RESONANCE IMAGING OF THE THORACIC&LUMBAR SPINE**

T2&T1 (DIXON) weighted, pre- and post-gadolinium sequences in multiple imaging planes are provided for review.

**SEX MAGNETIC RESONANCE IMAGING FINDINGS**

**F**  
 The spinal cord level with T5 to T10 presents is moderately swollen and presents a T2 & STIR diffuse & ill-defined hyperintense signal. Post contrast administration, a mild patchy contrast enhancement of the respective segment of the spinal cord is seen. Level with T0/T11, mild heterogeneous T2 hypointensity of the dorsal subarachnoid space is noted.

**AGE** 3 Months  
 The osseous and surrounding soft tissue structures of the thoracic spine are within normal limits.

**INTERPRETED BY** Sebastian Schaub, DVM  
 Dr. med. vet. DipECVDI  
 The osseous and soft tissue structures of the lumbar spine are within normal limits. The spinal cord along the lumbar spine presents smooth margins with the expected diameter and signal behavior.

**MAGNETIC RESONANCE IMAGING DIAGNOSIS**

- Intramedullary T2&STIR hyperintense lesion T2 to T10 with mild contrast enhancement
- Possible mild extramedullary hemorrhage level T10/T11

**HOSPITAL NAME**  
 Animal Health Partners

**INTERPRETATION OF THE FINDINGS & FURTHER RECOMMENDATIONS**

Given the acute onset of clinical signs, the odds for chronic ischemic myelopathy affecting a long segment of the thoracic spinal cord is the top differential. A differential is myelitis – but the acute onset of clinical signs is unusual. A CSF tap has already been performed for further workup. The extent of the affected segment of the spinal cord and the suspected mild extramedullary hemorrhage is suggestive for severe spinal cord damage and is increasing the risk for development of myelomalacia. The prognosis is considered guarded.

**REFERRING VET**  
 Dr. Stephanie Lovell

**INVOICE**

53617

**DATE**

8-20-22



**PATIENT**

Lola McQuay

**SPECIES**

Canine

**BREED**

Rottweiler

**SEX**

F

**AGE**

3 Months

**INTERPRETED BY**

Sebastian Schaub, DVM  
Dr. med. vet. DipECVDI

**HOSPITAL NAME**

Animal Health  
Partners

**REFERRING VET**

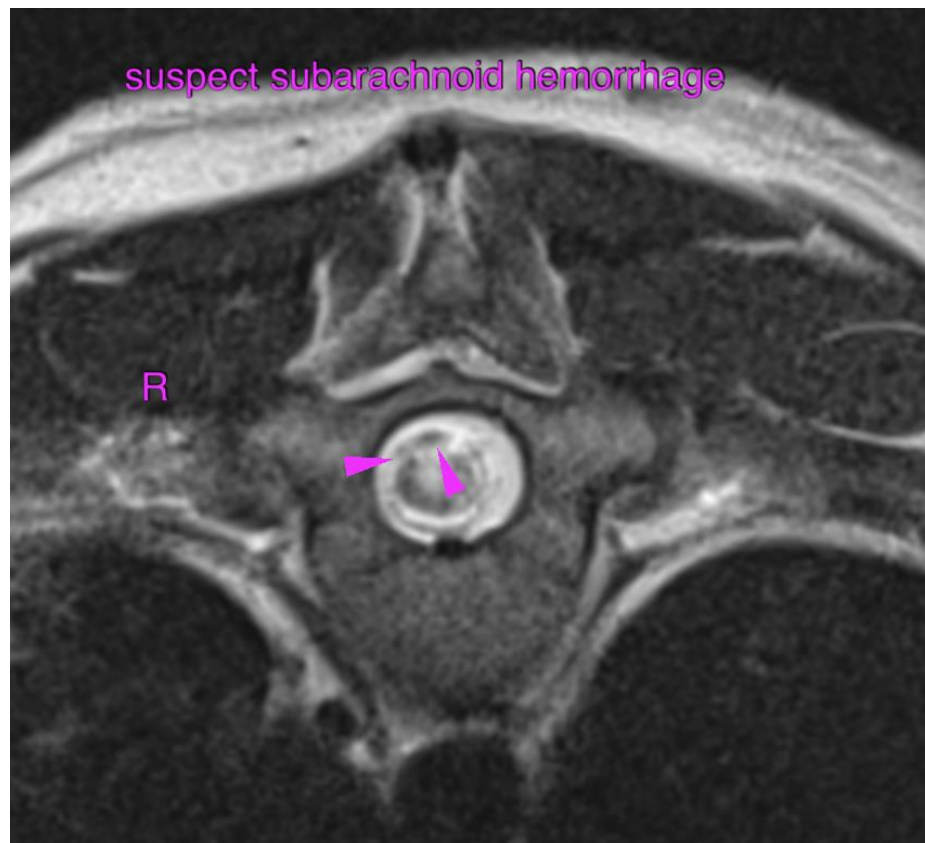
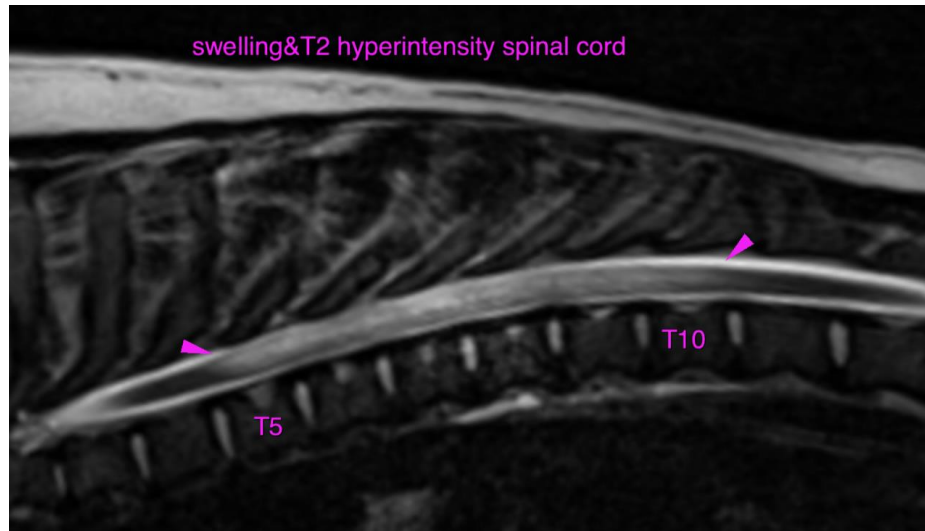
Dr. Stephanie Lovell

**INVOICE**

53617

**DATE**

8-20-22





**PATIENT**

Lola McQuay

The information and recommendations provided are based on the images presented by the referring veterinarian/sonographer. No evaluation can be communicated regarding pathology that was not visible in the image/video clips provided.

Thank you for this referral. If the clinical or image interpretation does not parallel your findings or if I can be of any further assistance please contact me.

**SPECIES**

Canine

**Sebastian Schaub**, Sebastian Schaub, DVM, Dr. med. vet. DipECVDI  
sebast.schaub@gmail.com

**BREED**

Rottweiler

**SEX**

F

**AGE**

3 Months

**INTERPRETED BY**

Sebastian Schaub, DVM  
Dr. med. vet. DipECVDI

**HOSPITAL NAME**

Animal Health  
Partners

**REFERRING VET**

Dr. Stephanie Lovell

**INVOICE**

53617

**DATE**

8-20-22