



PATIENT

Lillie Ramos

PRESENTING CLINICAL SIGNS

Chronic leg issues (not able to walk/stand up/weak in hind legs) that haven't improved with oral medications (gabapentin & prednisone). Spinal series rads performed on 8/16. Assessment: IVDD I3 I4, TE, Neoplasia, mod, Manx cat syndrome

SPECIES

Feline

COMPUTED TOMOGRAPHY OF THE THORACOLUMBAR SPINE

A plain CT study of thoracic & lumbar spine in a bone and soft tissue reconstruction is provided for review.

BREED

Pixiebob

COMPUTED TOMOGRAPHIC FINDINGS

The transverse process of L7 is contributing to the sacroiliac joint bilaterally. The sacrum consists only of one sacral vertebra, agenesis of the vertebral body S2&S3 is seen, but the lateral lamina is present. The caudate spine is shortened and malformed.

SEX

Female Spayed

COMPUTED TOMOGRAPHIC DIAGNOSIS

- Breed specific congenital malformation sacrum with agenesis vertebral body S2&S3
- Marked shortening and malformed caudate spine
- Symmetric lumbosacral transitional vertebral (Type II)

AGE

7 Years

INTERPRETATION OF THE FINDINGS & FURTHER RECOMMENDATIONS

Depending on development of clinical signs, sacrocaudal dysgenesis (Manx syndrome) is the presumptive diagnosis of for the presenting clinical signs. In case of strong clinical suspicion for underlying compressive myelopathy, recommend complementing workup by a myelographic CT study or MRI study of the spine.

INTERPRETED BY

Sebastian Schaub, DVM
Dr. med. vet. DipECVDI

HOSPITAL NAME

Westwood Regional
Veterinary Hospital

REFERRING VET

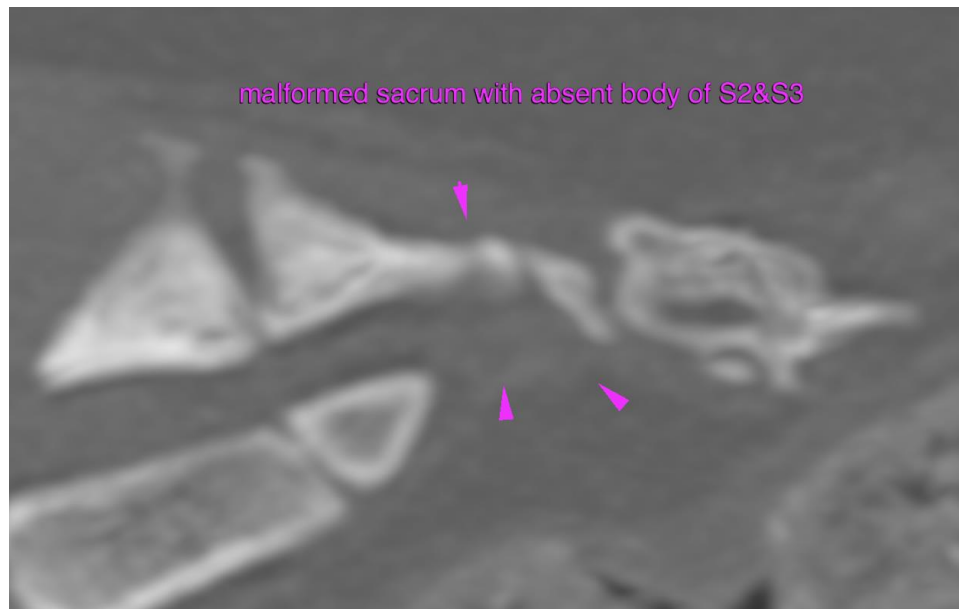
Cattiny

INVOICE

53614

DATE

8-20-22





PATIENT

Lillie Ramos

SPECIES

Feline

The information and recommendations provided are based on the images presented by the referring veterinarian/sonographer. No evaluation can be communicated regarding pathology that was not visible in the image/video clips provided.

BREED

Pixiebob

Thank you for this referral. If the clinical or image interpretation does not parallel your findings or if I can be of any further assistance please contact me.

SEX

Female Spayed

Sebastian Schaub, Sebastian Schaub, DVM, Dr. med. vet. DipECVDI
sebast.schaub@gmail.com

AGE

7 Years

INTERPRETED BY

Sebastian Schaub, DVM
Dr. med. vet. DipECVDI

HOSPITAL NAME

Westwood Regional
Veterinary Hospital

REFERRING VET

Cattiny

INVOICE

53614

DATE

8-20-22