



PATIENT

Casper Animal Life
Line Rescue League

PRESENTING CLINICAL SIGNS

Casper presented for evaluation of chronic nasal congestion for five years. nasal congestion
Anodontia
Abnormal PE/Chem/CBC/UA Results: Elevated WBC 33.92 (5.5-19.5) and Neutrophils 28.85
(3.12-12.58)

SPECIES

Feline

COMPUTED TOMOGRAPHY OF THE SKULL & THORAX

A high resolution pre- and post-contrast CT study of the skull and thorax are provided for review.

BREED

DSH

COMPUTED TOMOGRAPHIC FINDINGS

Skull

All teeth but triadan 301-303 are absent.

SEX

M

The nasal cavity presents the expected aerated spaces between thin & even conchae and turbinates with smooth mucosal lining. In the caudal third of the nasopharynx, focal narrowing of the nasopharynx is noted by a soft tissue attenuating and contrast enhancing mural ring.

AGE

5

Both temporomandibular joints present congruent joint spaces with even subchondral bone surfaces and are considered within normal limits.

INTERPRETED BY

Sebastian Schaub, DVM
Dr. med. vet. DipECVDI

Both tympanic bullae are aerated, the mucosal lining is not seen, the bony wall is smooth and thin. The external ear canals are within normal limits.

The brain presents no deviation from normal anatomy and symmetry. The brain parenchyma is homogeneous and within normal limits for attenuation and distribution of contrast enhancement. The ventricular system is non-dilated and symmetric.

HOSPITAL NAME

Animal Surgical
Center

The submandibular and medial retropharyngeal lymph nodes are small and elongated with a normal short-to-long-axis-ratio is < 0.5, the attenuation and contrast enhancement pattern is uniform.

Thorax

REFERRING VET

Dr. T. Infernuso

The most caudal aspect of the thorax is cropped by the field of view.

The bony and surrounding soft tissue structures are within normal limits.

INVOICE

47063

The sternal, cranial mediastinal and tracheobronchial lymph nodes are small elongated with a normal short-to-long-axis-ratio is < 0.5, the attenuation and contrast enhancement pattern is uniform and considered within normal limits.

The cardiovascular structures including the pulmonary vasculature are within normal limits.

DATE

8-20-21

Generalized mild thickening of the bronchial walls is visible.

The lung parenchyma presents the expected architecture and attenuation behavior.



PATIENT

Casper Animal Life
Line Rescue League

Small incidental gas pockets are seen within the esophageal lumen, there is no evidence of abnormal dilation.

COMPUTED TOMOGRAPHIC DIAGNOSIS

SPECIES

Feline

- Suspect nasopharyngeal stenosis
- Mild bronchial lung pattern
- History of full mouth dental extraction

BREED

DSH

INTERPRETATION OF THE FINDINGS & FURTHER RECOMMENDATIONS

The CT study is concerning for nasopharyngeal stenosis either by structure due to preceding inflammation or imperforated mucosal septum. There is no signs for active rhinitis. Recommend endoscopic evaluation of the nasopharynx to confirm the diagnosis as collapse secondary to general anesthesia might be a potential. If diagnosis is confirmed balloon dilation is a feasible treatment option, although if stenosis is of primary inflammatory origin, stenosis can reoccur.

SEX

M

The mild bronchial pattern indicates inflammatory lower airway disease, possibly subclinical and allergic as well as infectious causes (e.g., viral, bacterial, parasitic) are potentials. Correlate with clinical signs.

AGE

5

INTERPRETED BY

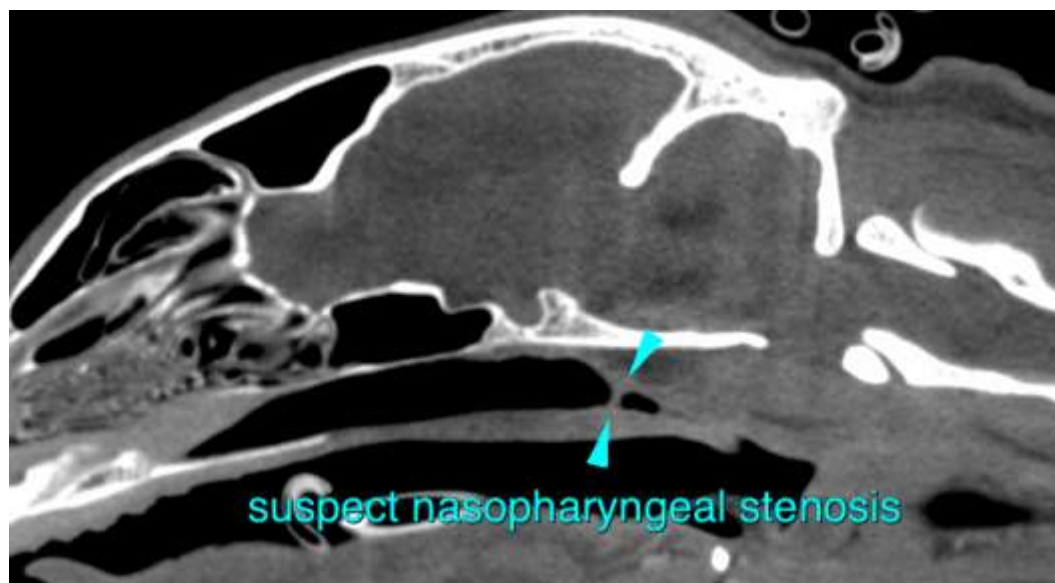
Sebastian Schaub, DVM
Dr. med. vet. DipECVDI

HOSPITAL NAME

Animal Surgical
Center

REFERRING VET

Dr. T. Infernuso



INVOICE

47063

DATE

8-20-21



PATIENT

Casper Animal Life
Line Rescue League

SPECIES

Feline

BREED

DSH

SEX

M

AGE

5

INTERPRETED BY

Sebastian Schaub, DVM
Dr. med. vet. DipECVDI

HOSPITAL NAME

Animal Surgical
Center

REFERRING VET

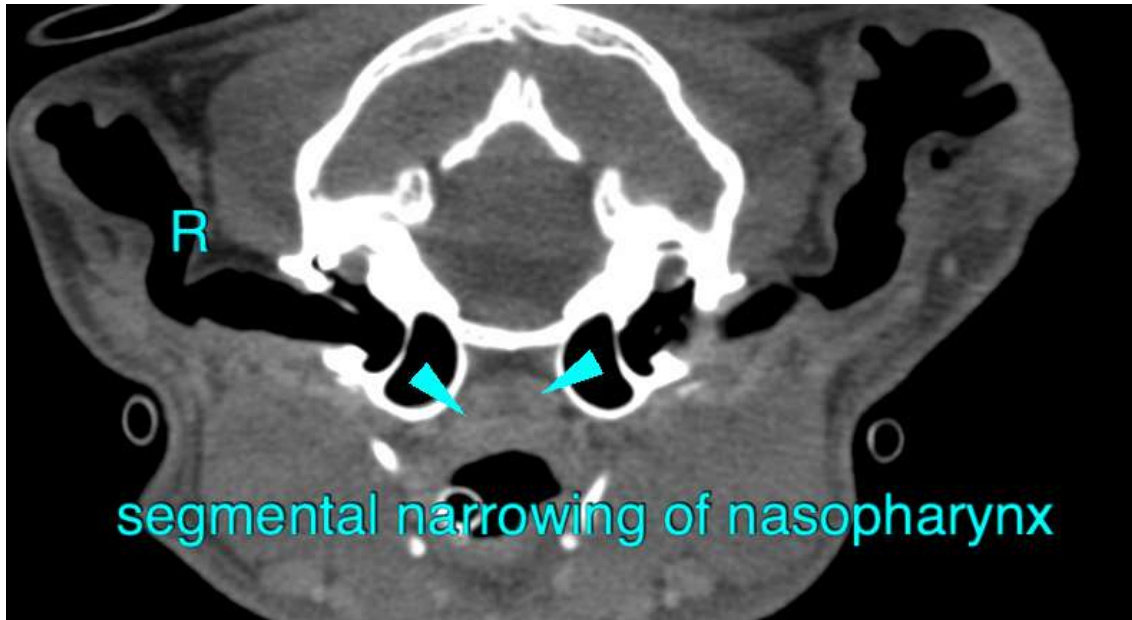
Dr. T. Infernuso

INVOICE

47063

DATE

8-20-21



The information and recommendations provided are based on the images presented by the referring veterinarian. No evaluation can be communicated regarding pathology that was not visible in the image/video clips provided.

Thank you for this referral. If the clinical or image interpretation does not parallel your findings or if I can be of any further assistance please contact me.

Sebastian Schaub, Sebastian Schaub, DVM, Dr. med. vet. DipECVDI
sebast.schaub@gmail.com