



PATIENT PRESENTING CLINICAL SIGNS

Ponyo Esposito Ponyo started sleeping a lot the past few days. No vomiting, or unsure if coughing/sneezing. He has to get neutered, so he has been separated from the other cats via an indoor catio so as to prevent reproduction. O unsure if he has ate or drank since hes been separated. He did have an URI infection that was treated with amoxicillin but that was over a month ago. Diagnosed with pyothorax at VEG Carle Place

SPECIES

Feline Abnormal PE/Chem/CBC/UA Results: -Green exudate removed from chest tube. Cytology revealed TNTC -CBC: neutropenia, leukocytosis, monocytosis

BREED

COMPUTED TOMOGRAPHY OF THE THORAX

DSH

A high resolution plain CT study of the thorax are provided for review.

COMPUTED TOMOGRAPHIC FINDINGS

SEX

A thoracic catheter is entering the right pleural cavity via the 9th intercostal space.

Male Intact

Accentuated in the right pleural cavity, a moderate amount of soft tissue attenuating material is appreciated with multiple interspersed gas bubbles. The lung lobes are retracted from the thoracic wall, R>>L, and present a decreased volume and ground glass attenuating parenchyma, R>L. The margins of the right lung lobes appear mildly irregular. The right middle lung lobe is collapsed and air-bronchograms are visible.

AGE

6 Months

The mediastinal structures are effaced by the soft tissue material in the pleural cavity.

INTERPRETED BY

Small incidental gas pockets are seen within the esophageal lumen, there is no evidence of abnormal dilation.

Sebastian Schaub, DVM
Dr. med. vet. DipECVDI

COMPUTED TOMOGRAPHIC DIAGNOSIS

- Pleural effusion, R>>L
- Mild right sided pneumothorax – can be iatrogenic due to placement of pleural catheter
- Atelectasis right middle lung lobe

HOSPITAL NAME

Animal Surgical Center - Oceanside

INTERPRETATION OF THE FINDINGS & FURTHER RECOMMENDATIONS

REFERRING VET

VEG Carle Place

The findings are fitting the history of confirmed pyothorax, R>>L. An underlying cause for the pleural pyothorax is not appreciated, it might be a sequela to bacterial translocation of pneumonia, perforating thoracic trauma or migrating foreign body (no foreign material is appreciated). The surface of the right lung lobes is mildly irregular undulating, possibly indicating chronic pleuritis. Further evaluation of the thoracic soft tissue structures in the plain CT study is not possible.

INVOICE

59614

DATE

8-2-23



PATIENT

Ponyo Esposito

SPECIES

Feline

BREED

DSH

SEX

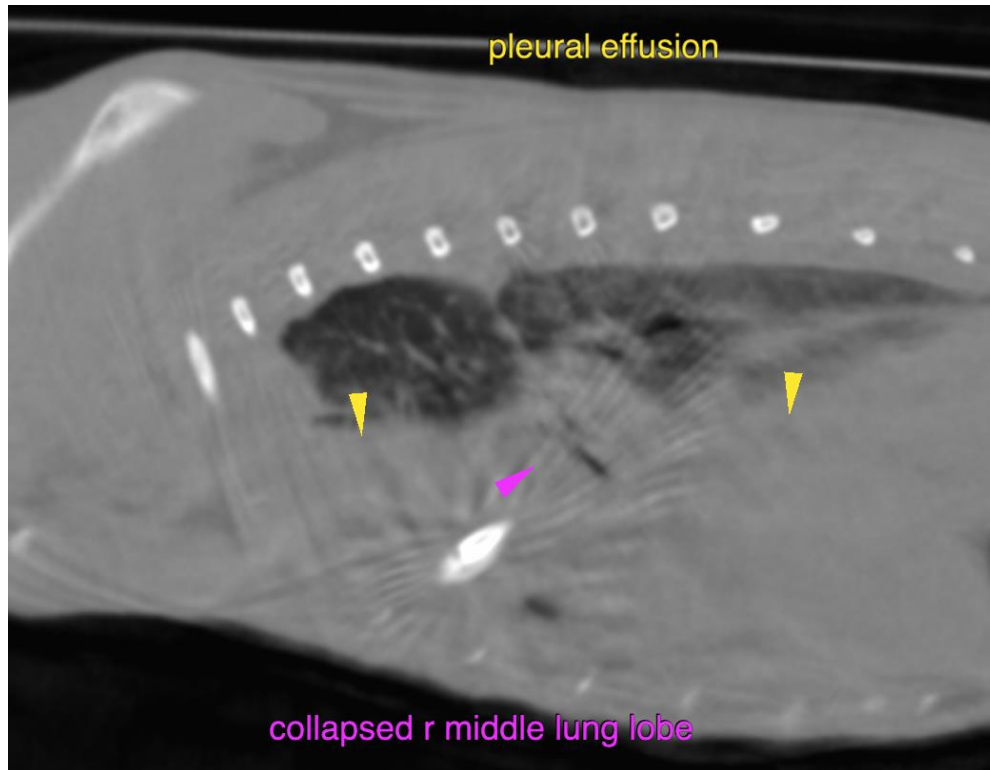
Male Intact

AGE

6 Months

INTERPRETED BY

Sebastian Schaub, DVM
Dr. med. vet. DipECVDI



HOSPITAL NAME

Animal Surgical
Center - Oceanside

The information and recommendations provided are based on the images presented by the referring veterinarian/sonographer. No evaluation can be communicated regarding pathology that was not visible in the image/video clips provided.

Thank you for this referral. If the clinical or image interpretation does not parallel your findings or if I can be of any further assistance please contact me.

REFERRING VET

VEG Carle Place

Sebastian Schaub, Sebastian Schaub, DVM, Dr. med. vet. DipECVDI
info@sonopath.com

INVOICE

59614

DATE

8-2-23