



**PATIENT**

Sadie Downing

**PRESENTING CLINICAL SIGNS**

For the past couple weeks, Sadie has been having weakness and difficulty pushing herself up w/ her back legs. Shortly after that started, pt also started favoring her front R leg. Then, for the past several days, Sadie has been excessively licking her R carpus. Pt is normally very active, but has been a lot less so lately.

**SPECIES**

Canine

Abnormal PE/Chem/CBC/UA Results: CREPITUS IN BOTH REAR RIGHT STIFLE MEDIAL BUTRESS LEFT STIFLE CLICK WITH RANGE OF MOTION DECREASED MUSCLE MASS LEFT HIND. Hip ROM appears normal RIGHT FRONT CARPUS SLIGHTLY THICK

**BREED**

Boxer Mix

**RADIOGRAPHIC STUDY OF THE PELVIS AND STIFLE JOINTS**

A complete set of radiographs of the pelvis and the stifle joints is provided for review.

**SEX**

Spayed Female

**RADIOGRAPHIC FINDINGS**

The osseous and surrounding soft tissue structures of the pelvis are within normal limits. Both coxofemoral joints present mild incongruity of the joint spaces and lateral widening of the subchondral sclerosis of the craniolateral acetabular rim is appreciated. Both coxofemoral joints present mild to moderate osteophyte new bone formation.

**AGE**

6 Years, 7 Months

Both stifle joints present smooth osseous margins. The right stifle joint presents mild intracapsular soft tissue swelling, partially effacing the infrapatellar fat-pad. The left stifle joint presents without evidence of intracapsular swelling.

**INTERPRETED BY**

Sebastian Schaub, DVM  
Dr. med. vet. DipECVDI

**RADIOGRAPHIC DIAGNOSIS**

- Mild degenerative osteoarthritis coxofemoral joints due to mild hip dysplasia
- Mild articular swelling right stifle joint
- Normal left stifle joint

**HOSPITAL NAME**

Elizabeth Animal Hospital

**INTERPRETATION OF THE FINDINGS & FURTHER RECOMMENDATIONS**

The radiographic study presents evidence of mild degenerative joint disease of the coxofemoral joints and signs of mild effusion of the right stifle joint (traumatic, degenerative, primary inflammatory). The clinical relevance of the findings for the presenting clinical signs is unclear. Rule out underlying neurological disease as well.

**REFERRING VET**

Kim Allyn, DVM

**INVOICE**

53211

**DATE**

8-2-22



**PATIENT**

Sadie Downing

**SPECIES**

Canine

**BREED**

Boxer Mix

**SEX**

Spayed Female

**AGE**

6 Years, 7 Months

**INTERPRETED BY**

Sebastian Schaub, DVM  
Dr. med. vet. DipECVDI

**HOSPITAL NAME**

Elizabeth Animal  
Hospital

**REFERRING VET**

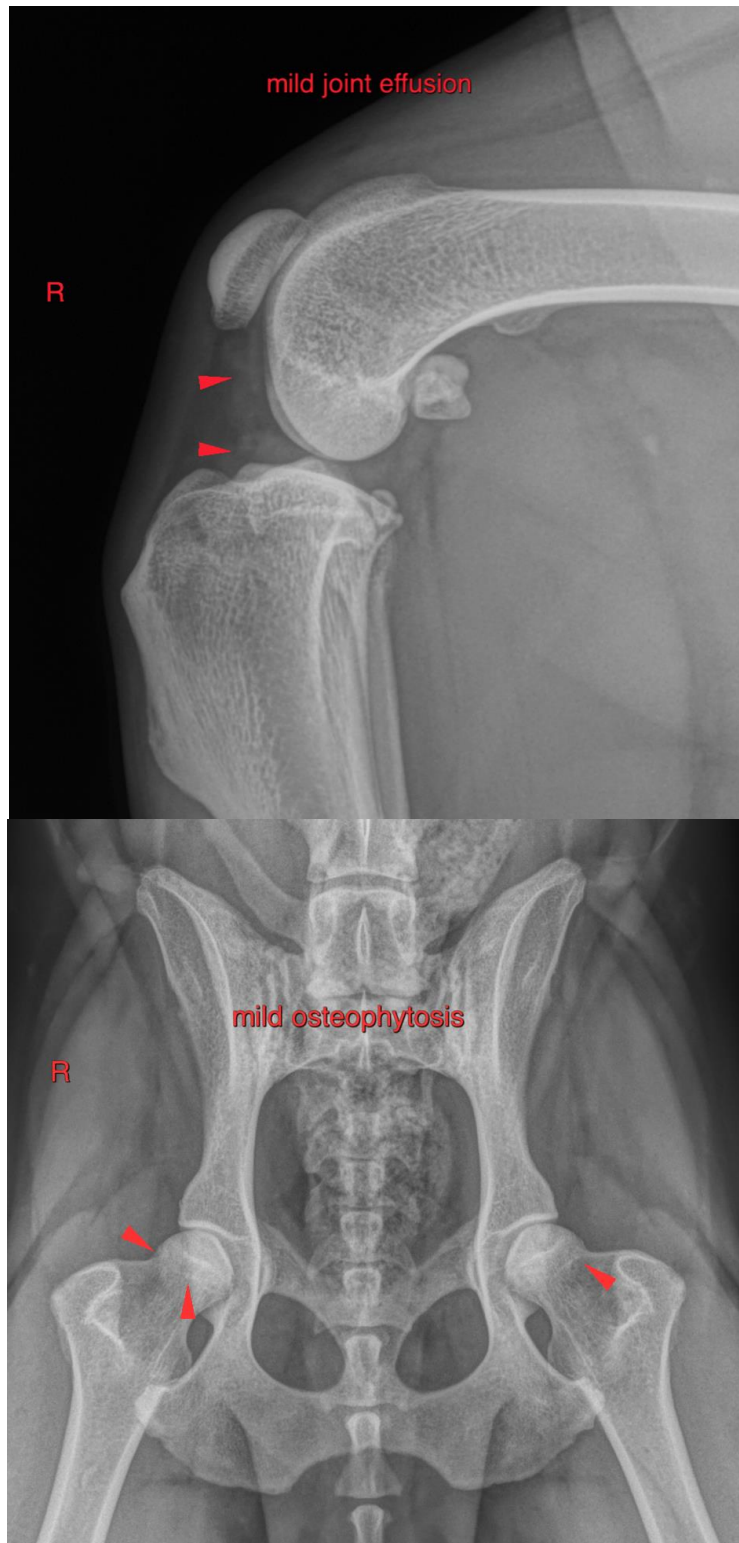
Kim Allyn, DVM

**INVOICE**

53211

**DATE**

8-2-22





**PATIENT**

Sadie Downing

The information and recommendations provided are based on the images presented by the referring veterinarian/sonographer. No evaluation can be communicated regarding pathology that was not visible in the image/video clips provided.

**SPECIES**

Canine

Thank you for this referral. If the clinical or image interpretation does not parallel your findings or if I can be of any further assistance please contact me.

**Sebastian Schaub**, Sebastian Schaub, DVM, Dr. med. vet. DipECVDI  
sebast.schaub@gmail.com

**BREED**

Boxer Mix

**SEX**

Spayed Female

**AGE**

6 Years, 7 Months

**INTERPRETED BY**

Sebastian Schaub, DVM  
Dr. med. vet. DipECVDI

**HOSPITAL NAME**

Elizabeth Animal  
Hospital

**REFERRING VET**

Kim Allyn, DVM

**INVOICE**

53211

**DATE**

8-2-22