



**PATIENT**

Jude Leone

**PRESENTING CLINICAL SIGNS**

Dog presented anorexia for 5-2 days. Vomiting some. Bloodwork was WNL. On physical exam dog is BAR. No pain in abdomen on palpation

**SPECIES**

K9

**RADIOGRAPHIC STUDY OF THE ABDOMEN**

Radiographs of the abdomen in three imaging planes are provided for review.

**RADIOGRAPHIC FINDINGS**

**BREED**

French Bulldog

Both coxofemoral joints present mild osteophyte new bone formation.

No abnormalities of the extraabdominal soft tissues are noted. The abdominal wall is smooth and thin.

The serosal detail is maintained throughout the peritoneal and retroperitoneal space.

**SEX**

M

The liver is appropriate in position, size and presents uniform opacity.

The splenic head is in the anticipated position and within normal limits for size and opacity. The splenic body and tail are considered normal for position, size, shape and opacity.

**AGE**

2 Years, 6 Months

Both kidneys are seen and present with normal size, shape, delineation and opacity. The urinary bladder is in its anticipated position. No radiopaque calculi are noted throughout the upper and lower urinary tract.

**INTERPRETED BY**

Sebastian Schaub, DVM  
Dr. med. vet. DipECVDI

The gastric rugal folds are prominent.

In the mid abdomen, a moderately gas distended small intestinal segment is appreciated. The remainder of the small intestinal loops are mildly distended by fluid and gas.

The colon is seen in the expected position and is empty.

**HOSPITAL NAME**

Blairstown Animal  
Hospital

**RADIOGRAPHIC DIAGNOSIS**

- Possible swelling gastric wall
- Mild to moderate gas dilation of the small intestinal loops
- Mild degenerative osteoarthritis coxofemoral joints bilaterally, due to hip dysplasia

**REFERRING VET**

Dr. Leal

**INTERPRETATION OF THE FINDINGS & FURTHER RECOMMENDATIONS**

The pattern of the gastrointestinal tract is most suggestive for gastritis/gastroenteritis. The gas distended small intestinal loop can be caused by reflexory relaxation and no specific sign for mechanical obstruction is appreciated. Recommend empirical management, if clinical signs are refractory to therapy, follow up radiographs or an abdominal ultrasound examination are recommended.

**INVOICE**

53237

**DATE**

8-2-22



**PATIENT**

Jude Leone

**SPECIES**

K9

**BREED**

French Bulldog

**SEX**

M

**AGE**

2 Years, 6 Months

**INTERPRETED BY**

Sebastian Schaub, DVM  
Dr. med. vet. DipECVDI

**HOSPITAL NAME**

Blairstown Animal  
Hospital

**REFERRING VET**

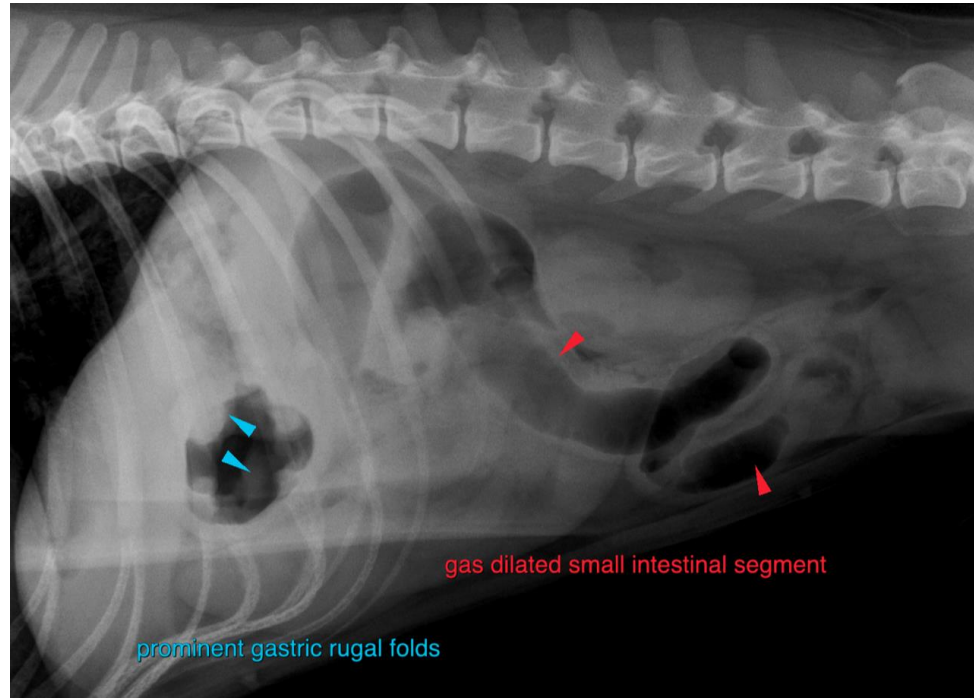
Dr. Leal

**INVOICE**

53237

**DATE**

8-2-22



The information and recommendations provided are based on the images presented by the referring veterinarian/sonographer. No evaluation can be communicated regarding pathology that was not visible in the image/video clips provided.

Thank you for this referral. If the clinical or image interpretation does not parallel your findings or if I can be of any further assistance please contact me.

**Sebastian Schaub**, Sebastian Schaub, DVM, Dr. med. vet. DipECVDI  
sebast.schaub@gmail.com