



PATIENT

Barkley Olds

SPECIES

Canine

BREED

Jack Russell Terrier

SEX

MN

AGE

4 Years

INTERPRETED BY

Sebastian Schaub, DVM
Dr. med. vet. DipECVDI

HOSPITAL NAME

Paws and Claws
Urgent Care

REFERRING VET

Alexis Rambaud

INVOICE

53238

DATE

8-2-22

PRESENTING CLINICAL SIGNS

Intermittent left-sided epistaxis. No foreign material noted with examination of nasal passages with otoscope.

Abnormal PE/Chem/CBC/UA Results: CBC/chem/PT/PTT and skull radiographs unremarkable.

COMPUTED TOMOGRAPHY OF THE SKULL

A high resolution pre- and post-contrast CT study of the skull is provided for review.

COMPUTED TOMOGRAPHIC FINDINGS

The pictured parts of the dentition are complete. The periodontal space of triadan 102 is moderately widened.

The nasal cavity presents the expected aerated spaces between thin & even conchae and turbinates with smooth mucosal lining. In the left nasal cavity, a very small amount of soft tissue attenuating material is attached to the nasal mucosal lining.

COMPUTED TOMOGRAPHIC DIAGNOSIS

- Small amount of exudate in nasal cavity, otherwise normal nasal cavity
- Periodontal disease 102

INTERPRETATION OF THE FINDINGS & FURTHER RECOMMENDATIONS

There is no evidence for neoplastic disease of the nasal cavity or foreign body related rhinitis or signs for mycotic rhinitis. Possible causes for epistaxis include immune mediated disease, non-specific rhinitis (e.g. lymphocytic plasmocytic), hyperviscosity syndrome (e.g. Leishmaniosis), other causes for coagulopathy or systemic hypertension. Rhinoscopy including biopsy can be considered as advanced diagnostic test.



PATIENT

Barkley Olds

SPECIES

Canine

BREED

Jack Russell Terrier

SEX

MN

AGE

4 Years

INTERPRETED BY

Sebastian Schaub, DVM
Dr. med. vet. DipECVDI

HOSPITAL NAME

Paws and Claws
Urgent Care

REFERRING VET

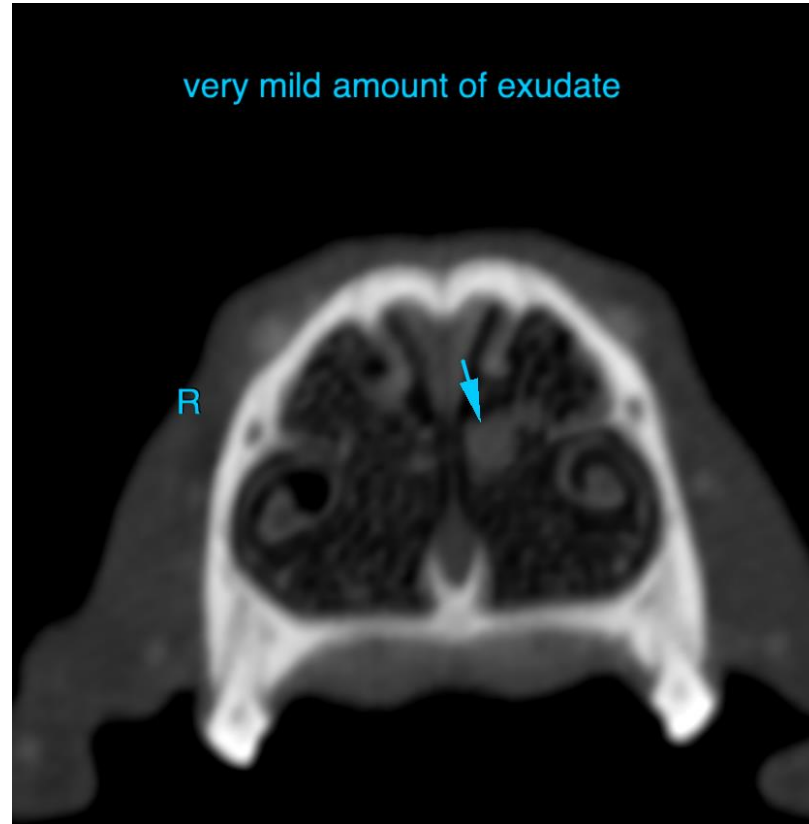
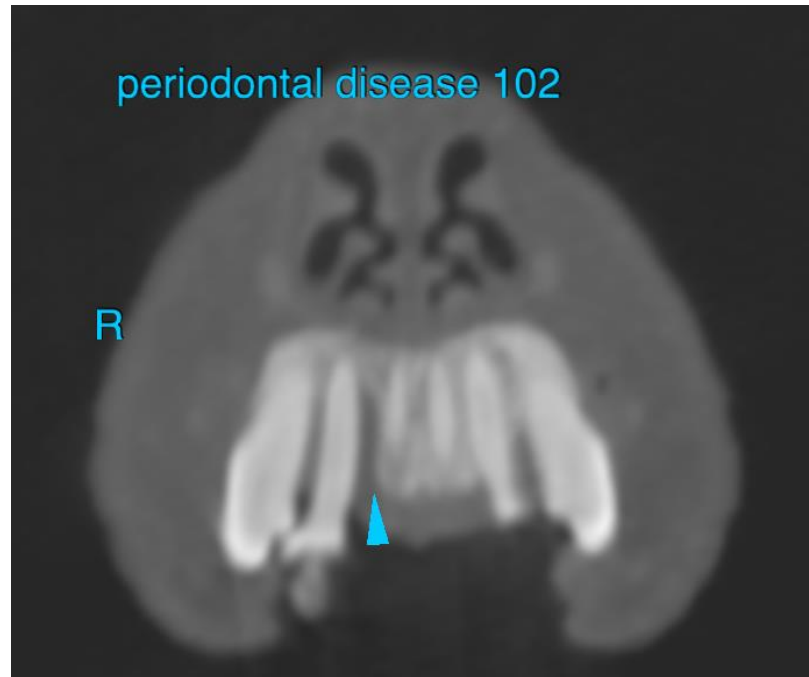
Alexis Rambaud

INVOICE

53238

DATE

8-2-22





PATIENT

Barkley Olds

SPECIES

Canine

BREED

Jack Russell Terrier

SEX

MN

AGE

4 Years

INTERPRETED BY

Sebastian Schaub, DVM
Dr. med. vet. DipECVDI

HOSPITAL NAME

Paws and Claws
Urgent Care

REFERRING VET

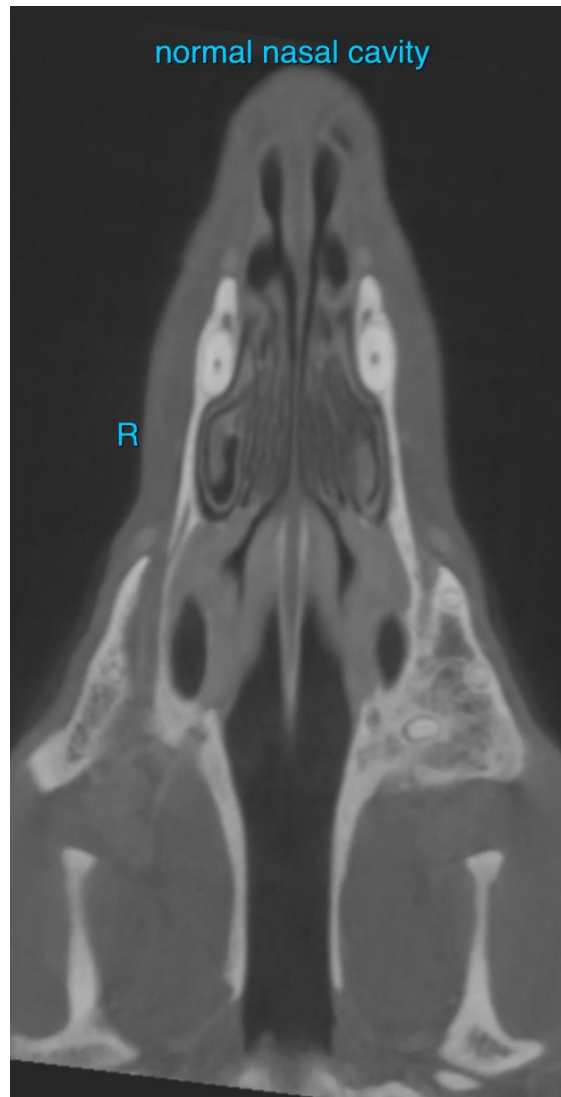
Alexis Rambaud

INVOICE

53238

DATE

8-2-22



The information and recommendations provided are based on the images presented by the referring veterinarian/sonographer. No evaluation can be communicated regarding pathology that was not visible in the image/video clips provided.

Thank you for this referral. If the clinical or image interpretation does not parallel your findings or if I can be of any further assistance please contact me.

Sebastian Schaub, Sebastian Schaub, DVM, Dr. med. vet. DipECVDI
sebast.schaub@gmail.com