



**PATIENT**

Bailey Allen

**PRESENTING CLINICAL SIGNS**

weight loss, exercise intolerance - more panting, slower and less willing, dental disease

**SPECIES**

Dog

**RADIOGRAPHIC STUDY OF THE THORAX**

Radiographs of the thorax in three imaging planes are provided for review. Images are provided in JPEG file format.

**BREED**

Shih Tzu

**RADIOGRAPHIC FINDINGS**

The surrounding bony structures are within normal limits.

The extrathoracic soft tissues present homogeneous without abnormalities.

The heart is of normal size and shape, there is no evidence of cardiac chamber or vascular enlargement. The pulmonary vasculature is within normal limits.

**SEX**

Neutered Male

The cranial mediastinum presents the expected soft tissue opacity. The mediastinal width is less than twice the width of the vertebral column at the same level.

The trachea is normal in diameter and presents the anticipated course. The luminal outline of the trachea is smooth.

**AGE**

11 Years, 6 Months

The bronchial tree presents with thin walls and tapers uniformly towards the periphery as expected.

**INTERPRETED BY**

Sebastian Schaub, DVM  
Dr. med. vet. DipECVDI

The lung parenchyma presents the expected architecture and opacity; the intrapulmonary vascular branching is seen up to the third order lung vessels.

The diaphragm is well delineated with even surface and the expected mild cranial bulging of the diaphragmatic cupola.

**HOSPITAL NAME**

Countryside Animal  
Clinic

**RADIOGRAPHIC DIAGNOSIS**

- Normal thorax

**REFERRING VET**

Kristina F. Cox, DVM

**INTERPRETATION OF THE FINDINGS & FURTHER RECOMMENDATIONS**

The radiographic study of the thorax presents without abnormalities. Check the abdomen, as there is a zone with heterogeneous mineralization - ultrasound would be ideal.

**INVOICE**

53239

**DATE**

8-2-22



**PATIENT**

Bailey Allen

**SPECIES**

Dog

**BREED**

Shih Tzu

**SEX**

Neutered Male

**AGE**

11 Years, 6 Months

**INTERPRETED BY**

Sebastian Schaub, DVM  
Dr. med. vet. DipECVDI

**HOSPITAL NAME**

Countryside Animal  
Clinic

**REFERRING VET**

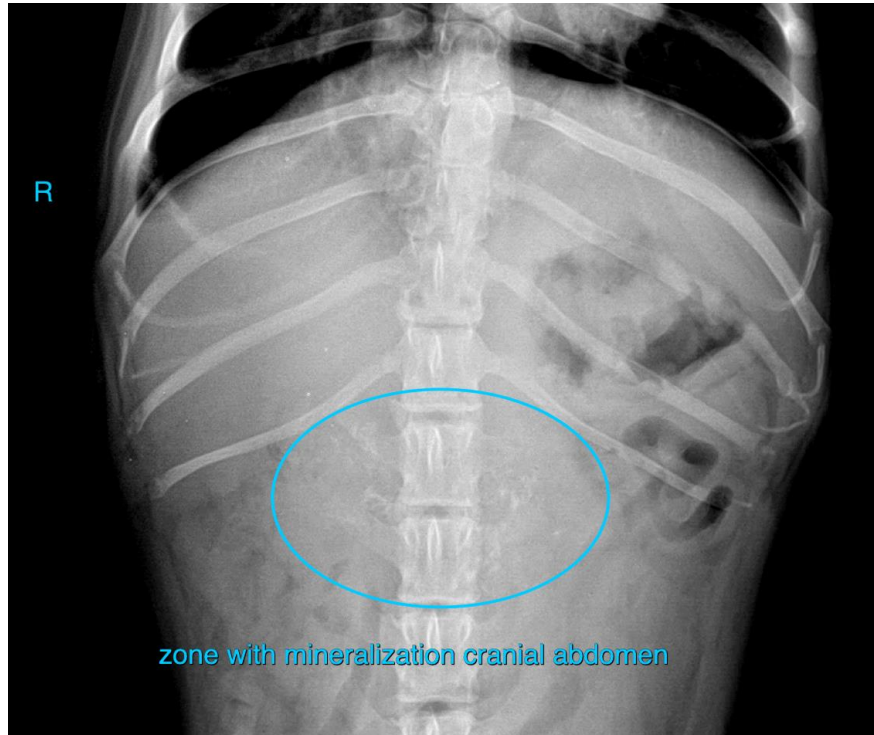
Kristina F. Cox, DVM

**INVOICE**

53239

**DATE**

8-2-22



The information and recommendations provided are based on the images presented by the referring veterinarian/sonographer. No evaluation can be communicated regarding pathology that was not visible in the image/video clips provided.

Thank you for this referral. If the clinical or image interpretation does not parallel your findings or if I can be of any further assistance please contact me.

**Sebastian Schaub**, Sebastian Schaub, DVM, Dr. med. vet. DipECVDI  
sebast.schaub@gmail.com