



PATIENT PRESENTING CLINICAL SIGNS

Nibbles Zimmerli History: P presents for weight loss despite good appetite. P has experienced progressive osteoarthritis around the same time that this started. BCS 1.5/9 on exam. Abnormal PE/Chem/CBC/UA Results: Low Na/K ratio, Mild azotemia. NSF on rest.

SPECIES RADIOGRAPHIC STUDY OF THE THORAX & ABDOMEN

Canine A complete set of radiographs of the thorax & abdomen is provided for review.

BREED RADIOGRAPHIC FINDINGS

Miniature Pinscher Thorax

SEX The surrounding bony structures are within normal limits.

Spayed Female The extrathoracic soft tissues present homogeneous without abnormalities.

AGE The heart is of normal size and shape, there is no evidence of cardiac chamber or vascular enlargement. The pulmonary vasculature is within normal limits.

16 Years The cranial mediastinum presents the expected soft tissue opacity. The mediastinal width is less than twice the width of the vertebral column at the same level.

INTERPRETED BY The trachea is normal in diameter and presents the anticipated course. The luminal outline of the trachea is smooth.

Sebastian Schaub, DVM Dr. med. vet. DipECVDI Generalized increased visibility of the bronchial tree is noted.

HOSPITAL NAME The lung parenchyma presents the expected architecture and opacity; the intrapulmonary vascular branching is seen up to the third order lung vessels.

Nimbus PH The diaphragm is well delineated with even surface and the expected mild cranial bulging of the diaphragmatic cupola.

REFERRING VET Abdomen

Dr. Saum Hadi The intervertebral disc spaces T13/L1 to L2/L3 are collapsed and the respective vertebral endplates present moderate spondylosis formation. The neuroforamen L2/L3 is opacified by irregular mineralized material.

INVOICE The ventral abdominal wall is tucked up – fitting the decreased body condition score.

23998 No abnormalities of the extraabdominal soft tissues are noted. The abdominal wall is smooth and thin.

DATE

8/19/23



PATIENT

Nibbles Zimmerli

The serosal detail is maintained throughout the peritoneal and retroperitoneal space.

The liver is appropriate in position, size and presents uniform opacity.

SPECIES

Canine

The splenic head is in the anticipated position and within normal limits for size and opacity.

The kidneys cannot be clearly delineated. The urinary bladder is empty and not clearly visualized – suspect caudal position in pelvic canal. No radiopaque calculi are noted throughout the upper and lower urinary tract.

BREED

Miniature Pinscher

The stomach is in its anticipated position and presents normal content.

The small intestinal loops are of even diameter and non-dilated, a small amount of gas is seen within the small intestinal loops and considered within normal limits.

SEX

Spayed Female

The colon is seen in the expected position and presents with appropriate content.

RADIOGRAPHIC DIAGNOSIS

AGE

16 Years

- Bronchial lung pattern
- Chronic discopathy T13/L1 to L2/L3
- Decreased body condition score

INTERPRETATION OF THE FINDINGS & FURTHER RECOMMENDATIONS

INTERPRETED BY

Sebastian Schaub,
DVM Dr. med. vet.
DipECVDI

The radiographic study reveals no abnormalities, explaining the history of weight loss.

The bronchial lung pattern is likely a sequela to mild mineralization of the bronchial walls – can be either an age related change or a sequela to hyperadrenocorticism.

HOSPITAL NAME

Nimbus PH

REFERRING VET

Dr. Saum Hadi

INVOICE

23998

DATE

8/19/23



PATIENT

Nibbles Zimmerli

SPECIES

Canine

BREED

Miniature Pinscher

SEX

Spayed Female

AGE

16 Years

INTERPRETED BY

Sebastian Schaub,
DVM Dr. med. vet.
DipECVDI

HOSPITAL NAME

Nimbus PH

REFERRING VET

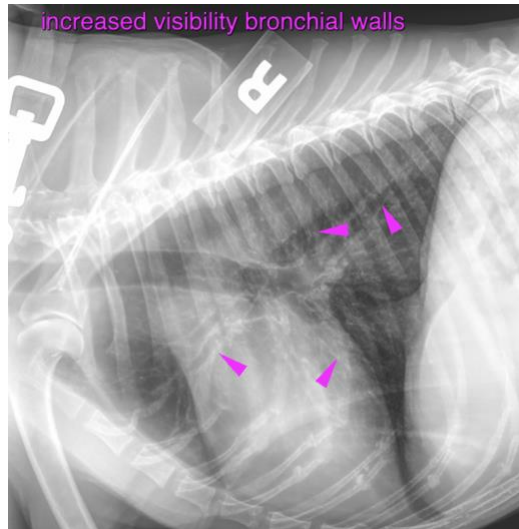
Dr. Saum Hadi

INVOICE

23998

DATE

8/19/23



The information and recommendations provided are based on the images presented by the referring veterinarian/sonographer. No evaluation can be communicated regarding pathology that was not visible in the image/video clips provided.

Thank you for this referral. If the clinical or image interpretation does not parallel your findings or if I can be of any further assistance please contact me.

Sebastian Schaub, Sebastian Schaub, DVM, Dr. med. vet. DipECVDI
info@sonopath.com