



**PATIENT PRESENTING CLINICAL SIGNS**

**Ebony Baehler**  
 O adopted in Feb 2022. Has coughed daily since then. Cough is described as unproductive, dry, rattling. No respiratory distress; Wheezing; Mostly indoors  
 Abnormal PE/Chem/CBC/UA Results: Open mouth breathing (hot weather, stress?); increased respiratory sounds-all fields; overweight

**SPECIES**

Feline

**RADIOGRAPHIC STUDY OF THE THORAX**

Radiographs of the thorax in three imaging planes are provided for review.

**BREED**

DSH

**RADIOGRAPHIC FINDINGS**

The surrounding bony structures are within normal limits.

The extrathoracic soft tissues present homogeneous without abnormalities.

**SEX**

Male Neutered

The heart is of normal size and shape, there is no evidence of cardiac chamber or vascular enlargement. The pulmonary vasculature is within normal limits.

The cranial mediastinum presents the expected soft tissue opacity. The mediastinal width is less than twice the width of the vertebral column at the same level.

**AGE**

3 Years

The trachea is normal in diameter and presents the anticipated course. The luminal outline of the trachea is smooth.

**INTERPRETED BY**

Sebastian Schaub, DVM  
 Dr. med. vet. DipECVDI

Generalized moderate peribronchial cuffing is noted. The lung parenchyma presents a generalized moderate ground-glass opacity.

The lung parenchyma presents the expected architecture and opacity; the intrapulmonary vascular branching is seen up to the third order lung vessels.

**HOSPITAL NAME**

Companion Animal  
 Clinic

The diaphragm is well delineated with even surface and the expected mild cranial bulging of the diaphragmatic cupola.

**RADIOGRAPHIC DIAGNOSIS**

- Broncho-interstitial lung pattern without evidence of air-trapping

**REFERRING VET**

Varinia Acosta

**INTERPRETATION OF THE FINDINGS & FURTHER RECOMMENDATIONS**

The broncho-interstitial lung pattern in combination with intermittent cough are compatible with feline bronchial disease ('feline asthma'). Superinfection may have caused deterioration of clinical signs – e.g. bacterial, Mycoplasma, viral, parasitic.

**INVOICE**

53609

**TECHNICAL COMMENTS**

Gloved human hands/fingers are seen in the primary beam, please consider radiation safety guidelines!

**DATE**

8-19-22



**PATIENT**

Ebony Baehler

**SPECIES**

Feline

**BREED**

DSH

**SEX**

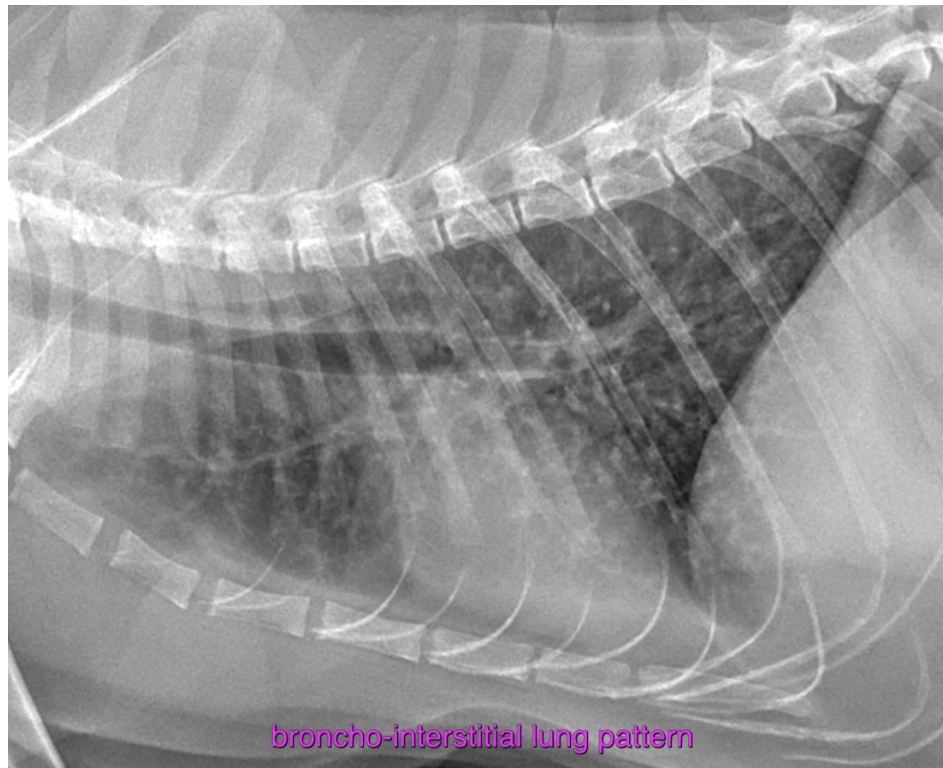
Male Neutered

**AGE**

3 Years

**INTERPRETED BY**

Sebastian Schaub, DVM  
Dr. med. vet. DipECVDI



**HOSPITAL NAME**

Companion Animal  
Clinic

**REFERRING VET**

Varinia Acosta

**INVOICE**

53609

**DATE**

8-19-22

The information and recommendations provided are based on the images presented by the referring veterinarian/sonographer. No evaluation can be communicated regarding pathology that was not visible in the image/video clips provided.

Thank you for this referral. If the clinical or image interpretation does not parallel your findings or if I can be of any further assistance please contact me.

**Sebastian Schaub**, Sebastian Schaub, DVM, Dr. med. vet. DipECVDI  
sebast.schaub@gmail.com