



PATIENT

Meli Aristizabal

PRESENTING CLINICAL SIGNS

Cough that has gotten worse lately. Looked down the trachea and didn't see anything of significance.

SPECIES

Canine

RADIOGRAPHIC STUDY OF THE THORAX

Radiographs of the thorax in three imaging planes are provided for review.

BREED

Aust Shepherd

RADIOGRAPHIC FINDINGS

The surrounding bony structures are within normal limits.

The extrathoracic soft tissues present homogeneous without abnormalities.

The heart is of normal size and shape, there is no evidence of cardiac chamber or vascular enlargement. The pulmonary vasculature is within normal limits.

SEX

FS

The cranial mediastinum presents the expected soft tissue opacity. The mediastinal width is less than twice the width of the vertebral column at the same level.

AGE

1 Year, 6 Months

An endotracheal tube is appreciated in the cervical tracheal segment. The trachea is normal in diameter and presents the anticipated course. The luminal outline of the trachea is smooth.

The lung parenchyma presents a generalized mild to moderate unstructured reticular lung pattern and generalized mild increased visibility of the bronchial walls is seen.

INTERPRETED BY

Sebastian Schaub, DVM
Dr. med. vet. DipECVDI

The diaphragm is well delineated with even surface and the expected mild cranial bulging of the diaphragmatic cupola.

RADIOGRAPHIC DIAGNOSIS

- Stationary broncho-interstitial lung pattern

HOSPITAL NAME

Sunridge Veterinary
Clinic

INTERPRETATION OF THE FINDINGS & FURTHER RECOMMENDATIONS

The interstitial component of the lung pattern might be accentuated by hypoinflation of the lung parenchyma due to general anesthesia. Overall the pulmonary pattern is stationary in comparison to the previous radiographic study and allergic/immune medial broncho-pneumopathy as well as infectious bronchopneumonitis (e.g. viral, bacterial, parasitic) need to be considered. If not done so yet, BAL would be ideal as advanced diagnostic tool.

REFERRING VET

Dr. Magill

INVOICE

53589

DATE

8-18-22



PATIENT

Meli Aristizabal

SPECIES

Canine

BREED

Aust Shepherd

SEX

FS

AGE

1 Year, 6 Months

INTERPRETED BY

Sebastian Schaub, DVM
Dr. med. vet. DipECVDI

HOSPITAL NAME

Sunridge Veterinary
Clinic

REFERRING VET

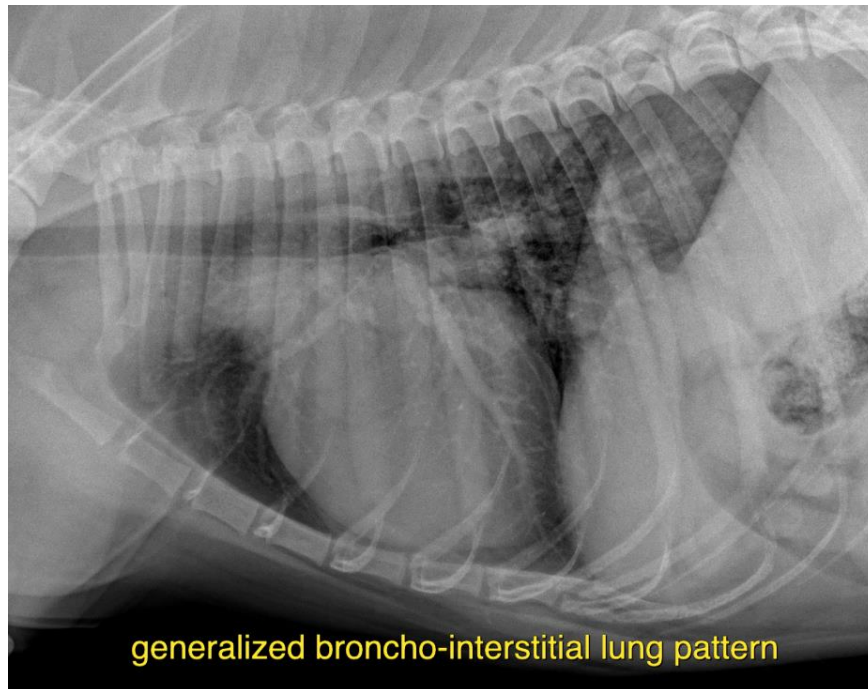
Dr. Magill

INVOICE

53589

DATE

8-18-22



The information and recommendations provided are based on the images presented by the referring veterinarian/sonographer. No evaluation can be communicated regarding pathology that was not visible in the image/video clips provided.

Thank you for this referral. If the clinical or image interpretation does not parallel your findings or if I can be of any further assistance please contact me.

Sebastian Schaub, Sebastian Schaub, DVM, Dr. med. vet. DipECVDI
sebast.schaub@gmail.com