



PATIENT

Lola McCarthy
Morgan Pet Clinic
6495VH-CT

PRESENTING CLINICAL SIGNS

Chronic nasal discharge (3 months) and respiratory noise. RDVM with nasal culture (see attached files) and poor response to targeted antimicrobial therapy from previous culture. Referral to us for imaging only today but with primary interest in upper airway anatomical changes. Owner notes right side primary issues - more problems at night and when eating.
Abnormal PE/Chem/CBC/UA Results: RDVM labs with AlkPhos 180 Increased MCHC at 39.3% Low abs EOS at 0.02

SPECIES

Canine

COMPUTED TOMOGRAPHY OF THE SKULL

A high resolution pre- and post-contrast CT study of the skull is provided for review.

BREED

French Bulldog

COMPUTED TOMOGRAPHIC FINDINGS

There is a breed specific brachycephalic conformation of the skull and rotation of the maxillary premolar teeth is noted. Triadan 105, 301, 305, 311, 405 and 411 are absent. A supernumerary triadan 201 is appreciated. Triadan 206, 207, 209, 302, 303, 401-403 present a mild to moderate widening of the periodontal space.

SEX

FS

The right nasal cavity is partially obliterated by fluid attenuating material, attached to the nasal mucosal lining and non-contrast enhancing soft tissue material is extending caudally up into the nasopharynx. Right sided mild aberrant caudal conchal growth is seen. The soft palate is moderately thickened and mildly elongated.

AGE

4 Years

Both temporomandibular joints present congruent joint spaces with even subchondral bone surfaces and are considered within normal limits.

INTERPRETED BY

Sebastian Schaub, DVM
Dr. med. vet. DipECVDI

The left tympanic bulla is filled with non-contrast enhancing soft tissue material, the osseous lining is smooth. The external ear canals are within normal limits.

The brain presents no deviation from normal anatomy and symmetry. The brain parenchyma is homogeneous and within normal limits for attenuation and distribution of contrast enhancement. The ventricular system is non-dilated and symmetric.

HOSPITAL NAME

Gentle Doctor Animal
Hospitals

The submandibular and medial retropharyngeal lymph nodes are small and elongated with a normal short-to-long-axis-ratio is < 0.5, the attenuation and contrast enhancement pattern is uniform.

COMPUTED TOMOGRAPHIC DIAGNOSIS

REFERRING VET

Pete Bashara, DVM

- Right sided rhinitis
- Right sided mild aberrant caudal conchal growth
- Thickened and mild elongated soft palate
- Left sided otitis media – suspect primary secretory
- Periodontal disease 105, 301, 305, 311, 405 and 411
- Supernumerary triadan 201
- Multiple absent teeth, see above

INVOICE

53576

INTERPRETATION OF THE FINDINGS & FURTHER RECOMMENDATIONS

DATE

8-18-22

No underlying cause for the right sided rhinitis can be specified, if not done so yet, rhinoscopy and retrograde evaluation of the nasopharynx are recommended to rule out nasal foreign body. There is no evidence of underlying oronasal fistula formation and if nasal foreign body can be rule



PATIENT

Lola McCarthy
Morgan Pet Clinic
6495VH-CT

out, the presumptive diagnosis is immune mediated non-specific rhinitis ± bacterial superinfection. Consider complementing workup by biopsy and sampling for microbial culture.

Check clinically if surgical correction of the soft palate would be beneficial.

SPECIES

Canine

BREED

French Bulldog

SEX

FS

AGE

4 Years

INTERPRETED BY

Sebastian Schaub, DVM
Dr. med. vet. DipECVDI

HOSPITAL NAME

Gentle Doctor Animal
Hospitals

REFERRING VET

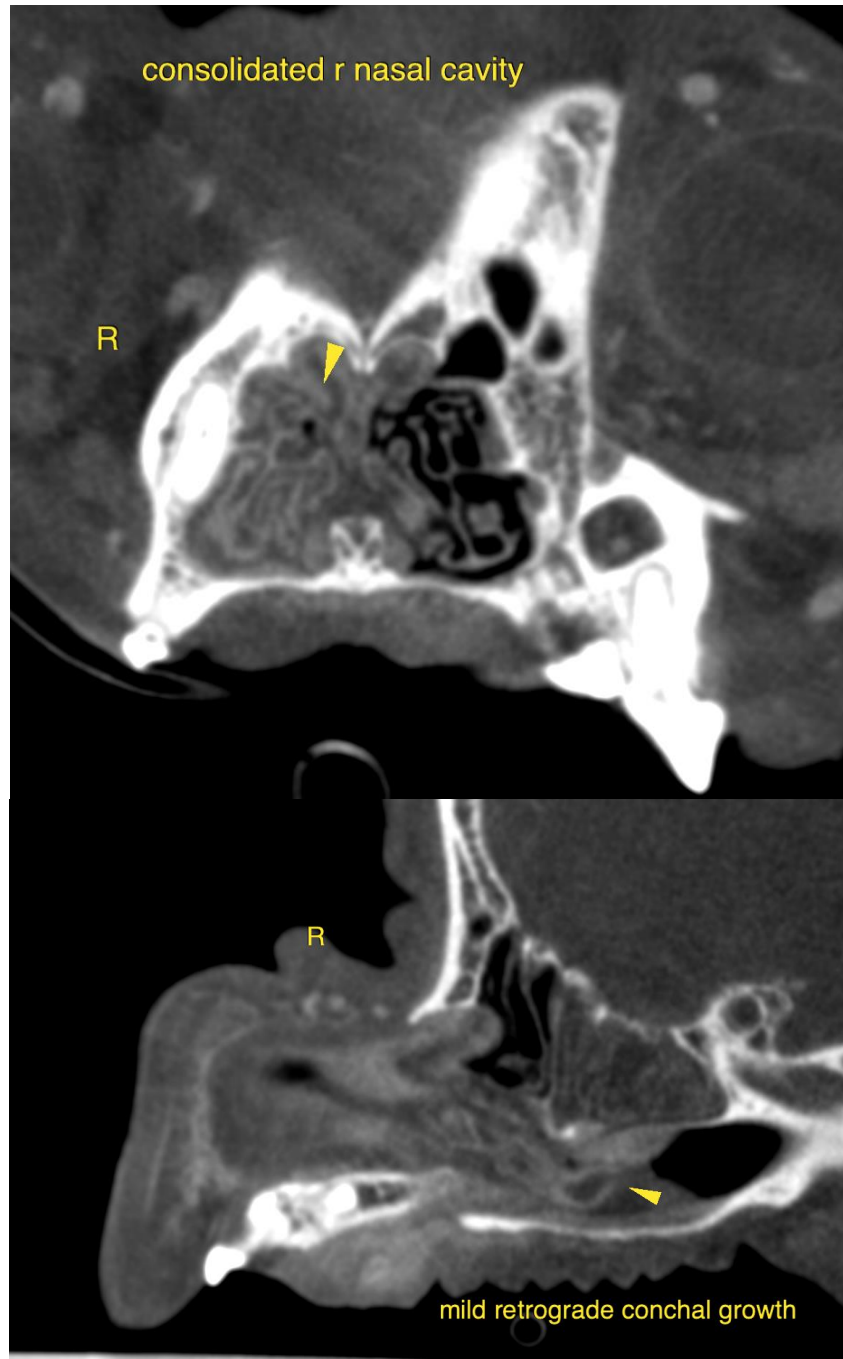
Pete Bashara, DVM

INVOICE

53576

DATE

8-18-22





PATIENT

Lola McCarthy
Morgan Pet Clinic
6495VH-CT

SPECIES

Canine

The information and recommendations provided are based on the images presented by the referring veterinarian/sonographer. No evaluation can be communicated regarding pathology that was not visible in the image/video clips provided.

BREED

French Bulldog

Thank you for this referral. If the clinical or image interpretation does not parallel your findings or if I can be of any further assistance please contact me.

Sebastian Schaub, Sebastian Schaub, DVM, Dr. med. vet. DipECVDI
sebast.schaub@gmail.com

SEX

FS

AGE

4 Years

INTERPRETED BY

Sebastian Schaub, DVM
Dr. med. vet. DipECVDI

HOSPITAL NAME

Gentle Doctor Animal
Hospitals

REFERRING VET

Pete Bashara, DVM

INVOICE

53576

DATE

8-18-22