



PATIENT PRESENTING CLINICAL SIGNS

Alfred Clyde History: Chronic Discharge out of right nasal passage. Dental procedure done in June 2021. Discharge and upper respiratory congestion were an issue before dental. Trail of antibiotics given, discharge improves some but not completely. Antibiotics discontinued 8/9/21

SPECIES

Canine Abnormal PE/Chem/CBC/UA Results: Biochemistry Profile- Canine Requisition/Performed Wed,18 Aug 2021 Result Range Units ALB 4.1 2.5-4.4 G/DL ALP 332* 20-150 U/L ALT 33 10-118 U/L AMY 623 200-1200 U/L TBIL 0.7* 0.1-0.6 MG/DL BUN 15 7-25 MG/DL CA++ 11.7 8.6-11.8 MG/DL PHOS 4.8 2.9-6.6 MG/DL CRE 0.7 0.3-1.4 MG/DL GLU 108 60-110 MG/DL NA+ 149 138-160 MMOL/L K+ 4.1 3.7-5.8 MMOL/L TP 7.2 5.4-8.2 G/DL GLOB 3.0 2.3-5.2 G/DL HEM 2+ NIL NIL LIP 3+ NIL NIL ICT 0 NIL NIL

BREED

Dachshund COMPUTED TOMOGRAPHIC STUDY OF THE SKULL

SEX

A high resolution plain CT study of the skull is provided for review.

Neutered Male

COMPUTED TOMOGRAPHIC FINDINGS

The tooth elements 101, 102, 104, 201, 203, 204 and 410 are absent. The periodontal space of triadan 108, 109, 210 is moderately widened.

AGE

9 Years 4 Months

In both nasal cavities a moderate amount of soft tissue material is attached to the surface of the conchal and turbinate structures. There is moderate destruction of the nasal conchal&turbinate structures bilaterally.

INTERPRETED BY

Sebastian Schaub,
DVM Dr. med. vet.
DipECVDI

Both temporomandibular joints present congruent joint spaces with even subchondral bone surfaces and are considered within normal limits.

Both tympanic bullae are aerated, the mucosal lining is not seen, the bony wall is smooth and thin. The external ear canals are within normal limits.

HOSPITAL NAME

State Avenue VC

The brain presents no deviation from normal anatomy and symmetry.

The right mandibular salivary gland is not appreciated within the field of view.

REFERRING VET

Dr. Raul Casas-Dolz

COMPUTED TOMOGRAPHIC DIAGNOSIS

- Destructive rhinitis, R>L
- Periodontal disease 108, 109, 210
- Multiple absent teeth, see above

INVOICE

12599

INTERPRETATION OF THE FINDINGS & FURTHER RECOMMENDATIONS

The computed tomographic findings are suggestive for chronic non-specific rhinitis.

DATE

8/18/21



PATIENT

Alfred Clyde

Possible causes of the rhinitis/sinusitis can be either viral or immune-mediated (most common form would be lymphocytic-plasmacytic) rhinitis with bacterial superinfection. Due to the conchal destruction fungal rhinitis is a potential but considered less likely. There are no signs for malignancy. Recommended rhinoscopy for further evaluation with sampling for culture and histopathology.

SPECIES

Canine

BREED

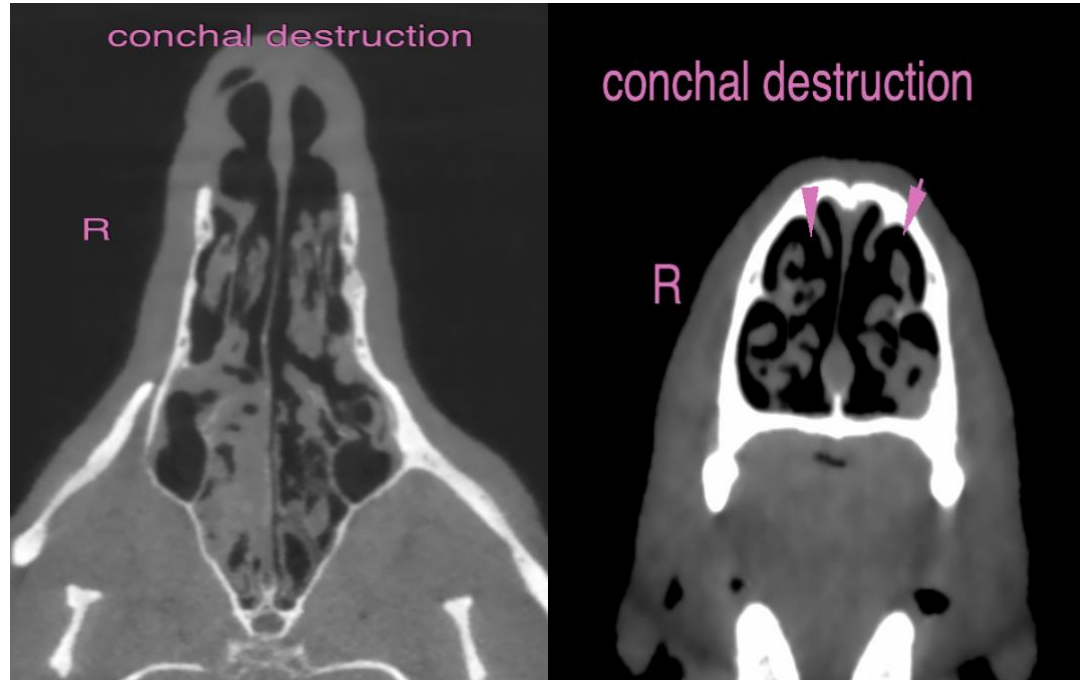
Dachshund

SEX

Neutered Male

AGE

9 Years 4 Months



INTERPRETED BY

Sebastian Schaub,
DVM Dr. med. vet.
DipECVDI

The information and recommendations provided are based on the images presented by the referring veterinarian. No evaluation can be communicated regarding pathology that was not visible in the image/video clips provided.

HOSPITAL NAME

State Avenue VC

Thank you for this referral. If the clinical or image interpretation does not parallel your findings or if I can be of any further assistance please contact me.

Sebastian Schaub, Sebastian Schaub, DVM, Dr. med. vet. DipECVDI
sebast.schaub@gmail.com

REFERRING VET

Dr. Raul Casas-Dolz

INVOICE

12599

DATE

8/18/21