



PATIENT PRESENTING CLINICAL SIGNS

PATIENT Skya Daniels
SPECIES Pt has been rapidly losing weight over the past few months. O is unsure of previous weight since she has not received veterinary care in several years. She vomited breakfast yesterday and has been lethargic, anorexic, and hiding for 24 hours. Vomited several times (not observed). Water intake and urination unknown.

Feline Abnormal PE/Chem/CBC/UA Results: hypokalemia (2.6), low-normal chloride (112). Mild hyperglycemia (179). AST elevated (92, N 0-48). Lymphopenia (0.66, N 0.92-6.88) with normal morphology.

BREED RADIOGRAPHIC STUDY OF THE ABDOMEN

DSH Radiographs of the abdomen in three imaging planes are provided for review.

RADIOGRAPHIC FINDINGS

SEX The vertebral endplates L5/L6 and L7/S1 present moderately spondylosis formation.

Spayed Female No abnormalities of the extraabdominal soft tissues are noted. The abdominal wall is smooth and thin.

The serosal detail is maintained throughout the peritoneal and retroperitoneal space.

AGE The hepatic volume is moderately increased the liver is protruding beyond the costal arch; the gastric axis is deviated caudally. The caudoventral hepatic margins are rounded.

12 Years

The splenic head is in the anticipated position and within normal limits for size and opacity.

INTERPRETED BY

Sebastian Schaub, DVM
 Dr. med. vet. DipECVDI

Both kidneys are seen and present with normal size, shape, delineation and opacity. The urinary bladder is in its anticipated position. No radiopaque calculi are noted throughout the upper and lower urinary tract.

HOSPITAL NAME

Northshore
 Veterinary Hospital

The stomach is in its anticipated position and is moderately distended by gas.

The small intestinal loops are of even diameter and non-dilated, a small amount of gas is seen within the small intestinal loops and considered within normal limits.

The colon is seen in the expected position and presents with appropriate content.

REFERRING VET

Sophie Lee, DVM

RADIOGRAPHIC DIAGNOSIS

- Aerophagia
- Mild hepatomegaly
- Spondylosis deformans

INVOICE

53555

INTERPRETATION OF THE FINDINGS & FURTHER RECOMMENDATIONS

The aerophagia can be a sequela to the vomiting, stress, pain or dyspnea and is considered as is considered as an incidental finding at this point. There is no evidence of radiopaque foreign material or signs for gastrointestinal mechanical obstruction

DATE

8-17-22

Potentials for the hepatomegaly include metabolic hepatic disease/steroid induced hepatopathy, hepatitis or neoplastic infiltration.

Complementing workup by an abdominal ultrasound examination might be beneficial.



PATIENT

Skya Daniels

SPECIES

Feline

BREED

DSH

SEX

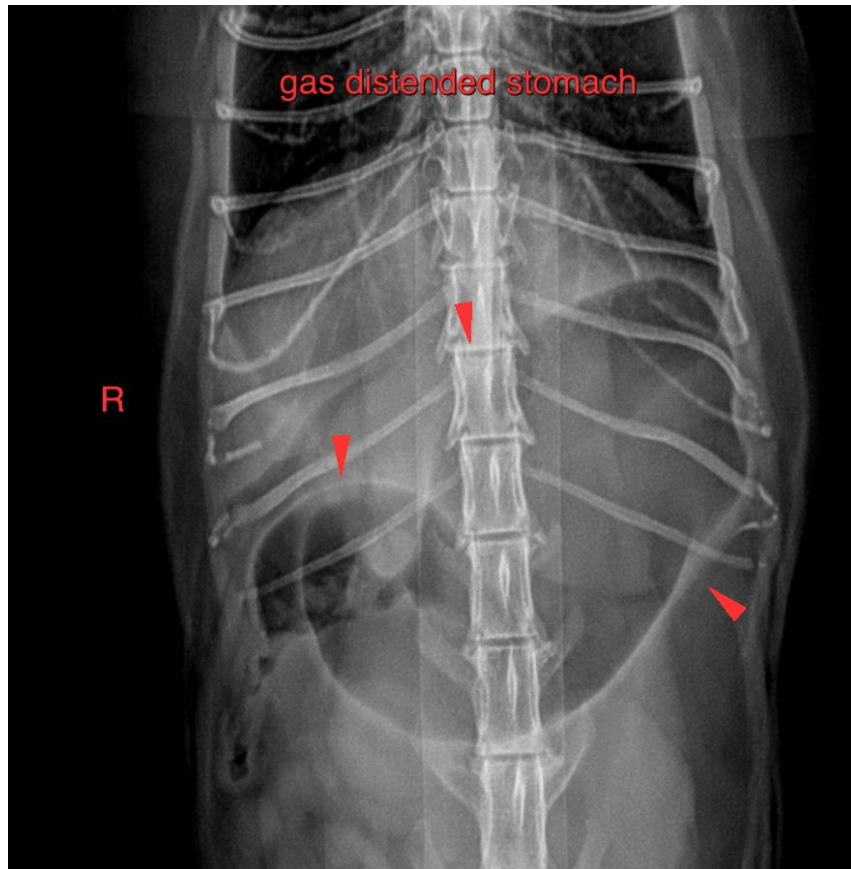
Spayed Female

AGE

12 Years

INTERPRETED BY

Sebastian Schaub, DVM
Dr. med. vet. DipECVDI



HOSPITAL NAME

Northshore
Veterinary Hospital

REFERRING VET

Sophie Lee, DVM

INVOICE

53555

DATE

8-17-22

The information and recommendations provided are based on the images presented by the referring veterinarian/sonographer. No evaluation can be communicated regarding pathology that was not visible in the image/video clips provided.

Thank you for this referral. If the clinical or image interpretation does not parallel your findings or if I can be of any further assistance please contact me.

Sebastian Schaub, Sebastian Schaub, DVM, Dr. med. vet. DipECVDI
sebast.schaub@gmail.com