



PATIENT

Nuggit Hickman

PRESENTING CLINICAL SIGNS

o reports that p has been having respiratory problems since before they got him - were aware of chronic respiratory problems when obtained from breeder. p has been in and out of hospitals this week due to respiratory distress. p is currently on an abx and lasix for pulmonary edema. p has had a full cardiac workup, but EC was unable to get bloodwork last night due to respiratory distress. o would like to get bloodwork done today and is interested in finding answers for p's condition NO AIRFLOW FROM LEFT NOSTRIL

SPECIES

Canine

COMPUTED TOMOGRAPHY OF THE SKULL & THORAX

BREED

A high resolution pre- and post-contrast CT study of the skull is provided for review.

Goldendoodle

COMPUTED TOMOGRAPHIC FINDINGS

Skull

SEX

The deciduous teeth and the tooth buds of the permanent teeth appear normal.

Male

The nasal cavity presents the expected aerated spaces between thin & even conchae and turbinates with smooth mucosal lining.

AGE

Both temporomandibular joints present congruent joint spaces with even subchondral bone surfaces and are considered within normal limits.

13 Weeks

Both tympanic bullae are aerated, the mucosal lining is not seen, the bony wall is smooth and thin. The external ear canals are within normal limits.

INTERPRETED BY

Sebastian Schaub, DVM
Dr. med. vet. DipECVDI

The brain presents no deviation from normal anatomy and symmetry. The brain parenchyma is homogeneous and within normal limits for attenuation and distribution of contrast enhancement. The ventricular system is non-dilated and symmetric.

HOSPITAL NAME

Aloha Pet & Bird
Hospital

The submandibular and medial retropharyngeal lymph nodes are small and elongated with a normal short-to-long-axis-ratio is < 0.5, the attenuation and contrast enhancement pattern is uniform.

Thorax

The bony and surrounding soft tissue structures are within normal limits.

REFERRING VET

Dr. Smith

The thymus can be appreciated in the cranioventral mediastinum, presenting as homogeneous soft tissue opacity with mild contrast enhancement, unremarkable.

The cardiovascular structures including the pulmonary vasculature are within normal limits.

INVOICE

53524

The bronchial tree presents with regular branching and tapers uniformly towards the periphery as expected, the bronchial walls are thin and smooth. The bronchus-to-artery ratio is within normal limits.

The lung parenchyma presents the expected architecture and attenuation behavior.

DATE

8-17-22

Small incidental gas pockets are seen within the esophageal lumen, there is no evidence of abnormal dilation.



PATIENT

Nuggit Hickman

COMPUTED TOMOGRAPHIC DIAGNOSIS

- Normal skull – including normal upper airways
- Normal thorax

SPECIES

Canine

INTERPRETATION OF THE FINDINGS & FURTHER RECOMMENDATIONS

The CT study of the skull is negative for disease. There is no evidence of obstruction of the upper airways (e.g. due to congenital malformation or inflammatory origin) or pathology of the lower airways. Rule out tracheal pathology that might be masked by the endotracheal tube. If there is evidence of oxygenation disorder, pulmonary microscopic arterio-venous shunts should be rule out by a cardiac echo using bubble study.

BREED

Goldendoodle

SEX

Male

AGE

13 Weeks

INTERPRETED BY

Sebastian Schaub, DVM
Dr. med. vet. DipECVDI

HOSPITAL NAME

Aloha Pet & Bird
Hospital

REFERRING VET

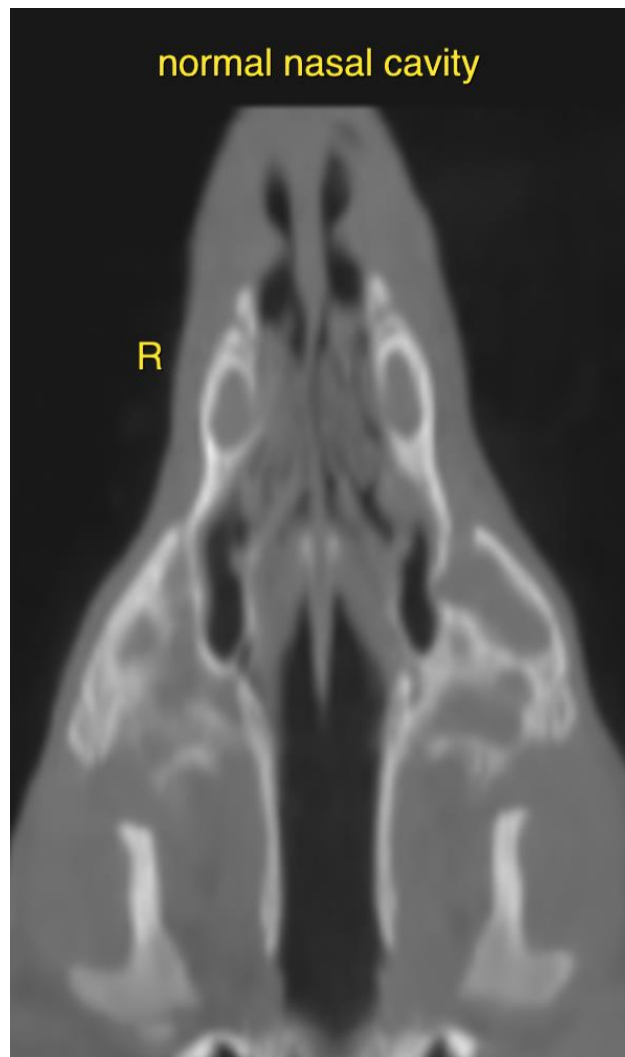
Dr. Smith

INVOICE

53524

DATE

8-17-22





PATIENT

Nuggit Hickman

SPECIES

Canine

BREED

Goldendoodle

SEX

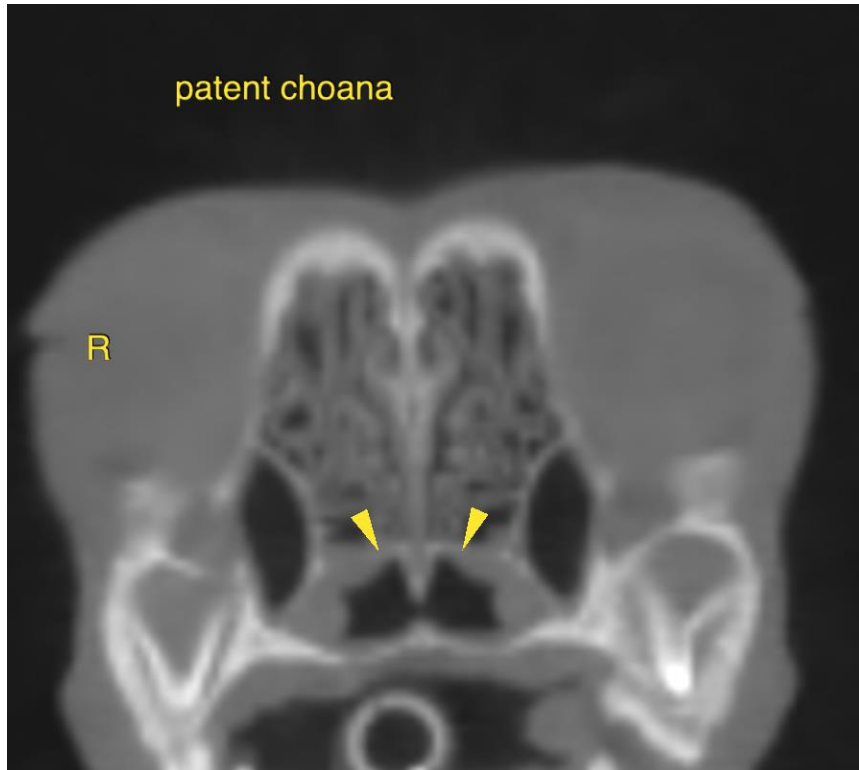
Male

AGE

13 Weeks

INTERPRETED BY

Sebastian Schaub, DVM
Dr. med. vet. DipECVDI



HOSPITAL NAME

Aloha Pet & Bird
Hospital

REFERRING VET

Dr. Smith

INVOICE

53524

DATE

8-17-22

The information and recommendations provided are based on the images presented by the referring veterinarian/sonographer. No evaluation can be communicated regarding pathology that was not visible in the image/video clips provided.

Thank you for this referral. If the clinical or image interpretation does not parallel your findings or if I can be of any further assistance please contact me.

Sebastian Schaub, Sebastian Schaub, DVM, Dr. med. vet. DipECVDI
sebast.schaub@gmail.com