



PATIENT PRESENTING CLINICAL SIGNS

Lola Garcia Came in Sunday for not walking. It all started Saturday, O took pt for a run after 6pm, patient ate her food and an hour later was laterally recumbent. Patient could've drunk toilet cleaner, unsure if could've gotten into something else. Patient wasn't moving or drinking water. Was inappetent and unable to hold herself up.

SPECIES
Canine
Abnormal PE/Chem/CBC/UA Results: CP deficit hind limbs, Deep/Superficial pain, diarrhea, hematuria

COMPUTED TOMOGRAPHY OF THE CERVICAL SPINE

BREED A high resolution plain and myelographic CT study of the cervical spine is provided for review.

Doberman COMPUTED TOMOGRAPHIC FINDINGS

Multifocal mild peripheral mineralization of the dural tube is seen along the cervical spine.

SEX Multifocal mild spondylosis formation is seen along the pictured cranial thoracic spine

Spayed Female After intrathecal contrast administration, level with the intervertebral disc space C5/C6, disc material is mild to moderately protruding into the vertebral canal, occupying approximately up to 20% of the cross-sectional area of the vertebral canal at the same level. The ventral subarachnoid space at the same level is compressed and the spinal cord is mildly distorted.

AGE
9 Years
COMPUTED TOMOGRAPHIC DIAGNOSIS

- Mild to moderate intervertebral disc protrusion C5/C6 with potential dynamic myelocompression
- Mild spondylosis formation cranial thoracic spine

INTERPRETED BY

Sebastian Schaub, DVM
Dr. med. vet. DipECVDI

INTERPRETATION OF THE FINDINGS & FURTHER RECOMMENDATIONS

HOSPITAL NAME

Mobile Pet Imaging

The CT study presents no specific abnormality, explaining the tetraparesis. The mild intervertebral disc protrusion C5/C6 can be a source for pain but is unlikely to be associated with the acute neurological deficits. Due to acute onset of clinical signs, ischemic myelopathy (e.g. fibrocartilagenous embolism) or acute non-compressive nucleus pulposus extrusion are considerations here.

REFERRING VET

Meaux

INVOICE

53529

DATE

8-17-22



PATIENT

Lola Garcia

SPECIES

Canine

BREED

Doberman

SEX

Spayed Female

AGE

9 Years

INTERPRETED BY

Sebastian Schaub, DVM
Dr. med. vet. DipECVDI

HOSPITAL NAME

Mobile Pet Imaging

REFERRING VET

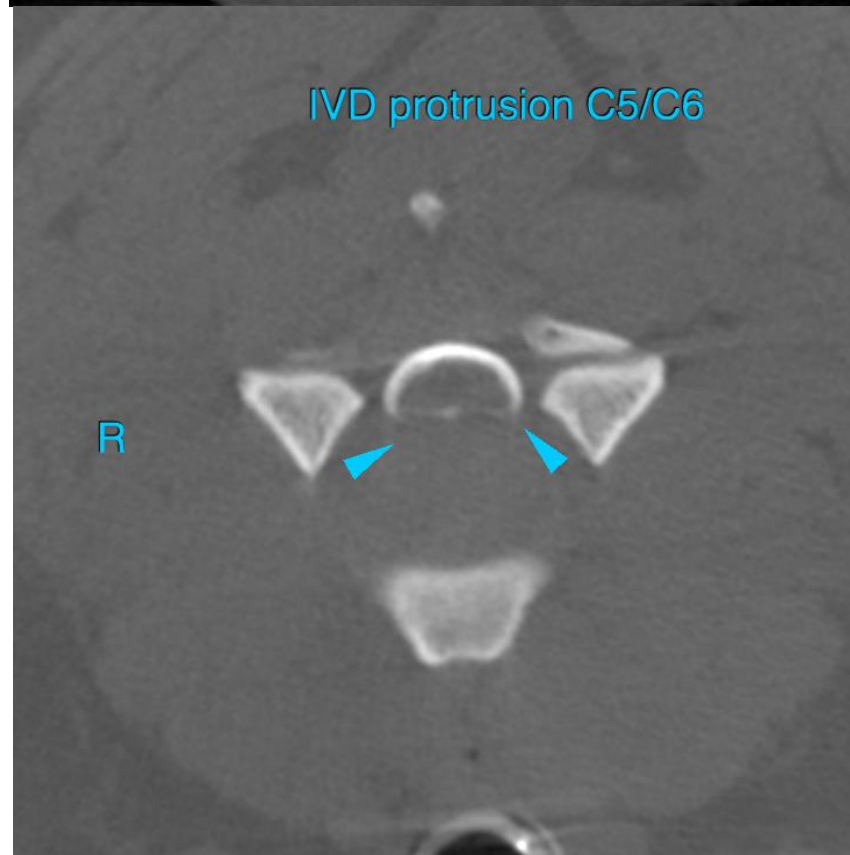
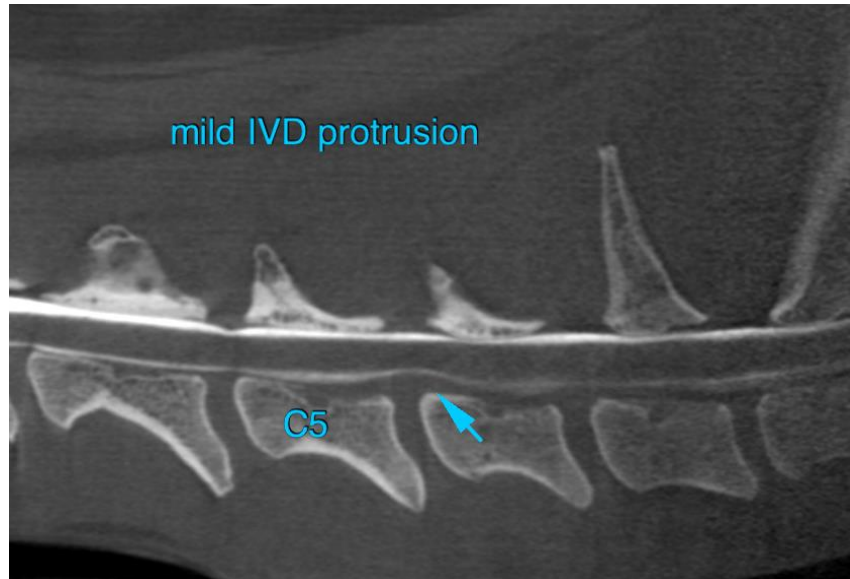
Meaux

INVOICE

53529

DATE

8-17-22





PATIENT

Lola Garcia

The information and recommendations provided are based on the images presented by the referring veterinarian/sonographer. No evaluation can be communicated regarding pathology that was not visible in the image/video clips provided.

SPECIES

Canine

Thank you for this referral. If the clinical or image interpretation does not parallel your findings or if I can be of any further assistance please contact me.

Sebastian Schaub, Sebastian Schaub, DVM, Dr. med. vet. DipECVDI
sebast.schaub@gmail.com

BREED

Doberman

SEX

Spayed Female

AGE

9 Years

INTERPRETED BY

Sebastian Schaub, DVM
Dr. med. vet. DipECVDI

HOSPITAL NAME

Mobile Pet Imaging

REFERRING VET

Meaux

INVOICE

53529

DATE

8-17-22