

**PATIENT**

Kit Kat Warner

PRESENTING CLINICAL SIGNS

Initially presented for misaligned jaw on 3/23/22, decreased appetite for past few months, and clicking noise when mouth is wide open. Indoor/outdoor with a leash. Currently not on any medications, eating Purina UR diet. O reports no recent trauma that he is aware of but there is a new puppy in the house who plays rough.

SPECIES

Feline

RADIOGRAPHIC STUDY OF THE SKULL

Radiographs of the skull in two orthogonal imaging planes are provided for review.

BREED

DMH

RADIOGRAPHIC FINDINGS

Superimposed on the right temporomandibular joint, a mineralizing mass with a coarse trabecular pattern is appreciated, likely originating from the right ramus of the mandible that presents loss of its normal slender conformation. The condylar process of the right mandible appears deformed. The mandible is deviated to the left.

SEX

MN

The remainder of the osseous and soft tissue structures of the skull are within normal limits.

AGE

6 Years

RADIOGRAPHIC DIAGNOSIS

- Monostotic osteoproliferative mass likely originating from the right ramus of the mandible
- Malocclusion due to left sided deviation of the mandible

INTERPRETED BY

Sebastian Schaub, DVM
Dr. med. vet. DipECVDI

INTERPRETATION OF THE FINDINGS & FURTHER RECOMMENDATIONS

There is a mineralizing mass originating likely originating from the ramus of the right mandible. Differentials include osteochondroma, osteochondrosarcoma, osteosarcoma, chondrosarcoma, other. FNA sampling ± biopsy of the mineralizing mass can be used for further differentiation. Consider testing for FeLV as osteochondroma can be associated with FeLV infection. A CT study can be used for further evaluation of the extend of the mass and decision making if surgery is a treatment option.

HOSPITAL NAME

Reid Veterinary
Hospital

REFERRING VET

Dr. Sawyer Reid

INVOICE

53553

DATE

8-17-22



PATIENT

Kit Kat Warner

SPECIES

Feline

BREED

DMH

SEX

MN

AGE

6 Years

INTERPRETED BY

Sebastian Schaub, DVM
Dr. med. vet. DipECVDI

HOSPITAL NAME

Reid Veterinary
Hospital

REFERRING VET

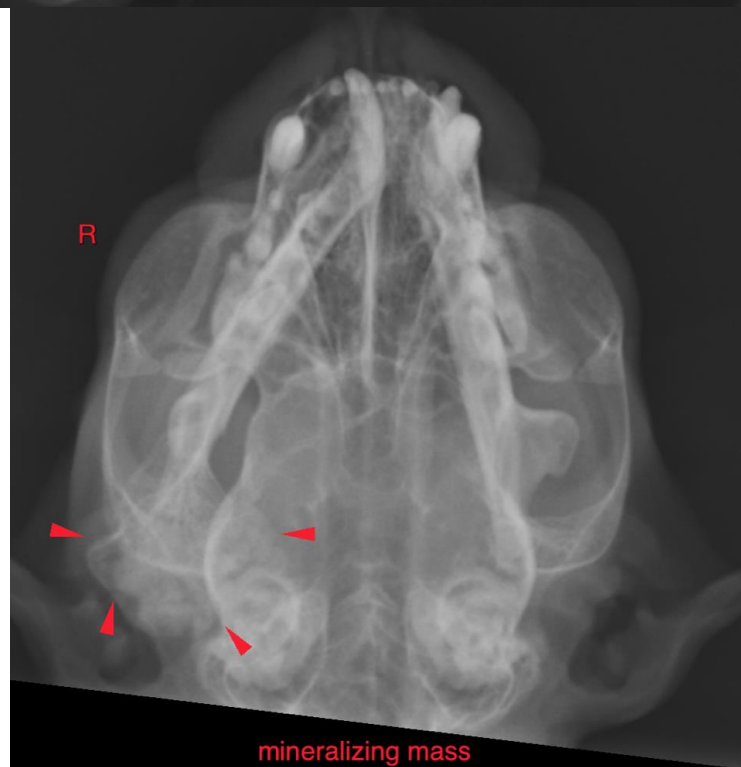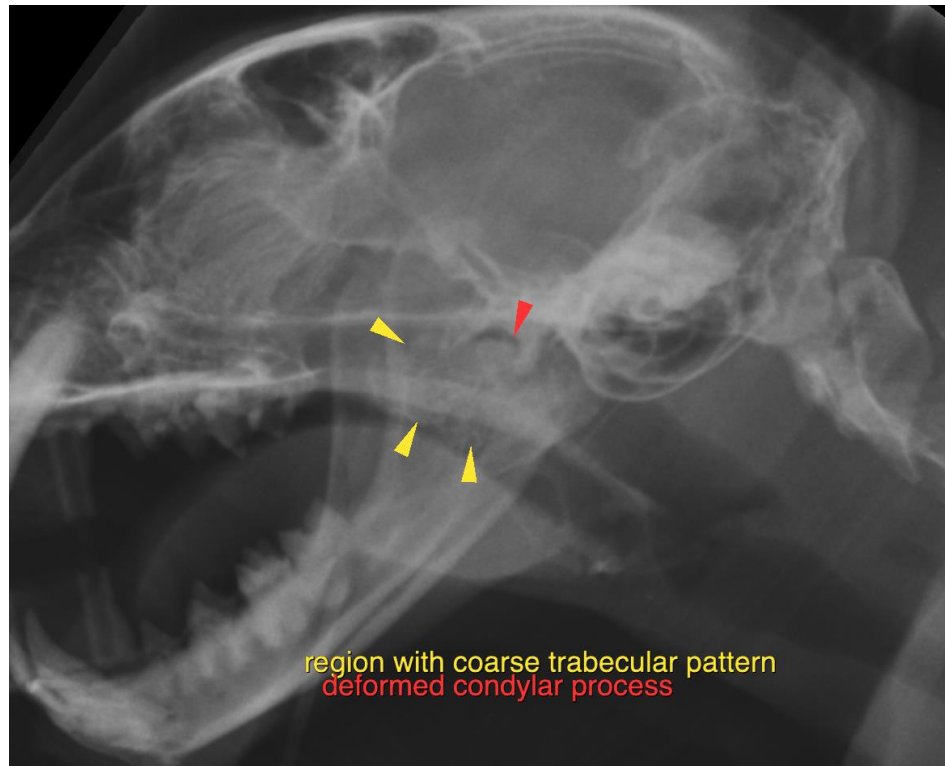
Dr. Sawyer Reid

INVOICE

53553

DATE

8-17-22





PATIENT

Kit Kat Warner

The information and recommendations provided are based on the images presented by the referring veterinarian/sonographer. No evaluation can be communicated regarding pathology that was not visible in the image/video clips provided.

SPECIES

Feline

Thank you for this referral. If the clinical or image interpretation does not parallel your findings or if I can be of any further assistance please contact me.

BREED

DMH

Sebastian Schaub, Sebastian Schaub, DVM, Dr. med. vet. DipECVDI
sebast.schaub@gmail.com

SEX

MN

AGE

6 Years

INTERPRETED BY

Sebastian Schaub, DVM
Dr. med. vet. DipECVDI

HOSPITAL NAME

Reid Veterinary
Hospital

REFERRING VET

Dr. Sawyer Reid

INVOICE

53553

DATE

8-17-22