



PATIENT

Flynn Postma

PRESENTING CLINICAL SIGNS

Straining to defecate, defecating outside the litterbox, CANNOT PASS THERMOMETER RECTALLY, -UNCOMFORTABLE, RECTUM LOOKS INFLAMMED
Abnormal PE/Chem/CBC/UA Results: BW done in Feb 2022- WNL

SPECIES

Feline

RADIOGRAPHIC STUDY OF THE ABDOMEN

A right & left lateral view of the abdomen is provided for review.

BREED

Oriental Shorthair

RADIOGRAPHIC FINDINGS

The surrounding bony structures are within normal limits.

No abnormalities of the extraabdominal soft tissues are noted. The abdominal wall is smooth and thin.

SEX

Male Neutered

The serosal detail is maintained throughout the peritoneal and retroperitoneal space.

The liver is appropriate in position, size and presents uniform opacity.

AGE

4 Years

Both kidneys are seen and present with normal size, shape, delineation and opacity. The urinary bladder is in its anticipated position. No radiopaque calculi are noted throughout the upper and lower urinary tract.

The stomach is in its anticipated position and is empty.

INTERPRETED BY

Sebastian Schaub, DVM
Dr. med. vet. DipECVDI

The small intestinal loops are of even diameter and non-dilated, a small amount of gas is seen within the small intestinal loops and considered within normal limits.

The colon is seen in the expected position and contains a moderate amount of gas and small amount of fecal material. The caudal aspect of the rectum presents mild irregular undulating wall

HOSPITAL NAME

St. Catherine's Animal
Hospital

RADIOGRAPHIC DIAGNOSIS

- Undulating caudal mural margins rectum
- Empty gastrointestinal tract

REFERRING VET

Dr. Jui Gokhale

INTERPRETATION OF THE FINDINGS & FURTHER RECOMMENDATIONS

The undulating caudal margins of the rectum can present normal mucosal folds, mucosal thickening (e.g. proctitis) fecal material adhering to the wall or intraluminal polypoid lesion protruding from the wall. No additional abnormalities of the abdomen are appreciated, explaining the presenting clinical signs, there is no evidence of constipation. Further definition workup warrants clinical evaluation and rectal examination.

INVOICE

53552

DATE

8-17-22



PATIENT

Flynn Postma

SPECIES

Feline

BREED

Oriental Shorthair

SEX

Male Neutered

AGE

4 Years

INTERPRETED BY

Sebastian Schaub, DVM
Dr. med. vet. DipECVDI

HOSPITAL NAME

St. Catherine's Animal
Hospital

REFERRING VET

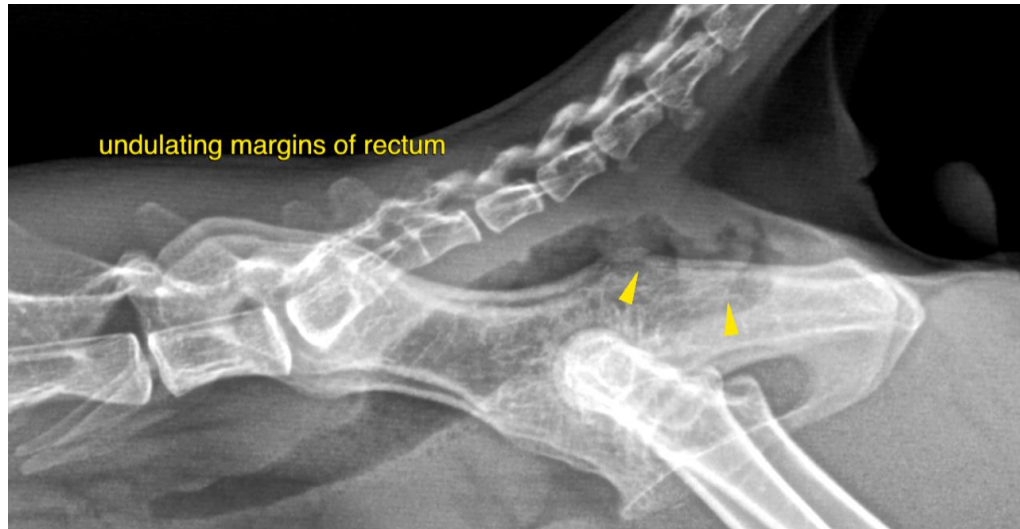
Dr. Jui Gokhale

INVOICE

53552

DATE

8-17-22



The information and recommendations provided are based on the images presented by the referring veterinarian/sonographer. No evaluation can be communicated regarding pathology that was not visible in the image/video clips provided.

Thank you for this referral. If the clinical or image interpretation does not parallel your findings or if I can be of any further assistance please contact me.

Sebastian Schaub, Sebastian Schaub, DVM, Dr. med. vet. DipECVDI
sebast.schaub@gmail.com