



**PATIENT PRESENTING CLINICAL SIGNS**

Dottie Smith Cough 2 weeks duration, rest of PE unremarkable  
Abnormal PE/Chem/CBC/UA Results: unremarkable labowork

**SPECIES RADIOGRAPHIC STUDY OF THE THORAX**

Canine Radiographs of the thorax in three imaging planes are provided for review.

**BREED RADIOGRAPHIC FINDINGS**

Chow Mix The periarticular bones of both shoulder joints present mild osteophyte new bone formation.

The extrathoracic soft tissues present homogeneous without abnormalities.

The heart is of normal size and shape, there is no evidence of cardiac chamber or vascular enlargement. The pulmonary vasculature is within normal limits.

**SEX** The cranial mediastinum presents the expected soft tissue opacity. The mediastinal width is less than twice the width of the vertebral column at the same level.

MN The trachea is normal in diameter and presents the anticipated course. The luminal outline of the trachea is smooth.

**AGE** The bronchial walls present a mild increased visibility.

10 Years, 1 Month The lung parenchyma presents the expected architecture and opacity; the intrapulmonary vascular branching is seen up to the third order lung vessels.

**INTERPRETED BY** The diaphragm is well delineated with even surface and the expected mild cranial bulging of the diaphragmatic cupola.

Sebastian Schaub, DVM  
Dr. med. vet. DipECVDI

**RADIOGRAPHIC DIAGNOSIS**

- Mild bronchial pattern
- Degenerative osteoarthritis shoulder joints bilaterally

**HOSPITAL NAME**

Gentle Doctor Animal Hospital

**INTERPRETATION OF THE FINDINGS & FURTHER RECOMMENDATIONS**

The mild bronchial pattern is likely accentuated by mild mineralization of the bronchial walls – possible age related change or can indicate hyperadrenocorticism. A potential is bronchitis – primary inflammatory non-infectious, such as lymphocytic plasmocytic, eosinophilic, mixed is considered more likely than infectious bronchitis. If clinical signs are refractory to empirical therapy, bronchoscopy including BAL can be used as advanced diagnostic tool.

**REFERRING VET**

Dr. Megan Belfiore

**INVOICE**

53519

**DATE**

8-17-22



**PATIENT**

Dottie Smith

**SPECIES**

Canine

**BREED**

Chow Mix

**SEX**

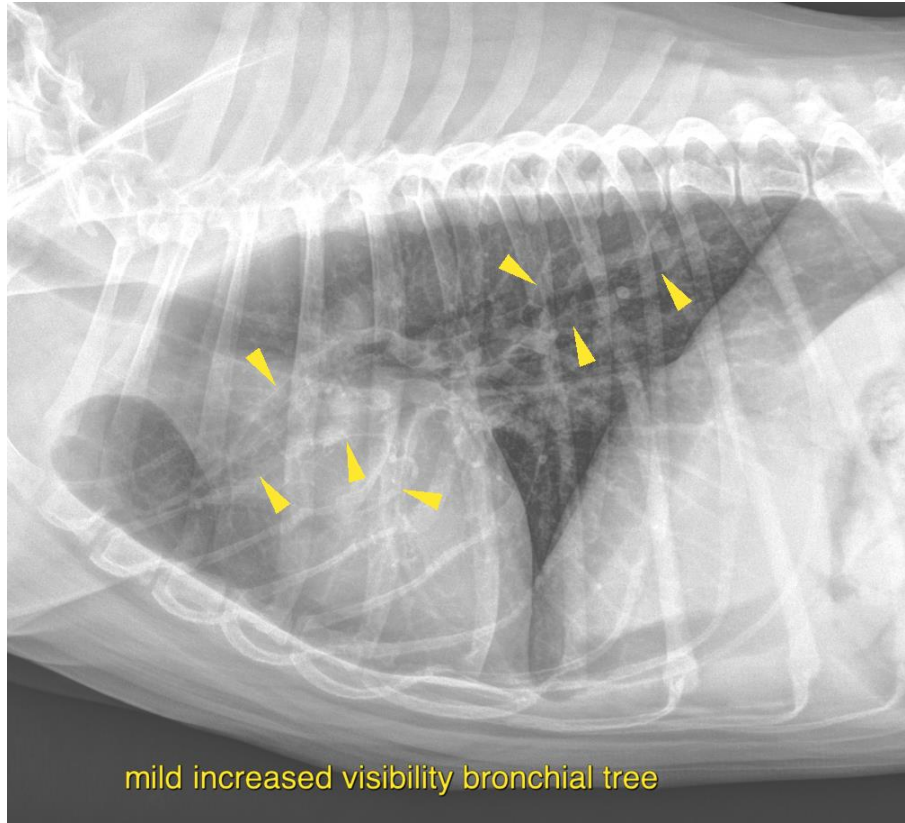
MN

**AGE**

10 Years, 1 Month

**INTERPRETED BY**

Sebastian Schaub, DVM  
Dr. med. vet. DipECVDI



mild increased visibility bronchial tree

**HOSPITAL NAME**

Gentle Doctor Animal  
Hospital

**REFERRING VET**

Dr. Megan Belfiore

**INVOICE**

53519

**DATE**

8-17-22

The information and recommendations provided are based on the images presented by the referring veterinarian/sonographer. No evaluation can be communicated regarding pathology that was not visible in the image/video clips provided.

Thank you for this referral. If the clinical or image interpretation does not parallel your findings or if I can be of any further assistance please contact me.

**Sebastian Schaub**, Sebastian Schaub, DVM, Dr. med. vet. DipECVDI  
sebast.schaub@gmail.com