



PATIENT

Bentley Mumm

PRESENTING CLINICAL SIGNS

For the last 1-2 weeks Bentley has been having a hard time getting up in the morning and he seems stiff at night as well. He still runs around like normal but after laying around for a while he seems stiff.

SPECIES

Canine

Abnormal PE/Chem/CBC/UA Results: DECREASED MUSCLE MASS IN BOTH REAR, DISLIKES EXTENSION OF HIPS

BREED

Australian Shepherd

RADIOGRAPHIC STUDY OF THE PELVIS

Radiographs of the pelvis in two orthogonal imaging planes are provided for review.

RADIOGRAPHIC FINDINGS

The osseous and surrounding soft tissue structures of the pelvis are within normal limits. Both coxofemoral joints present smooth osseous margins and congruent joint spaces.

SEX

MN

RADIOGRAPHIC DIAGNOSIS

- Normal pelvis & coxofemoral joints

AGE

6 Years

INTERPRETATION OF THE FINDINGS & FURTHER RECOMMENDATIONS

The radiographic study of the pelvis presents without abnormalities. Rule out underlying discopathy, such as degenerative lumbosacral stenosis.

INTERPRETED BY

Sebastian Schaub, DVM
Dr. med. vet. DipECVDI

HOSPITAL NAME

Elizabeth Animal
Hospital

REFERRING VET

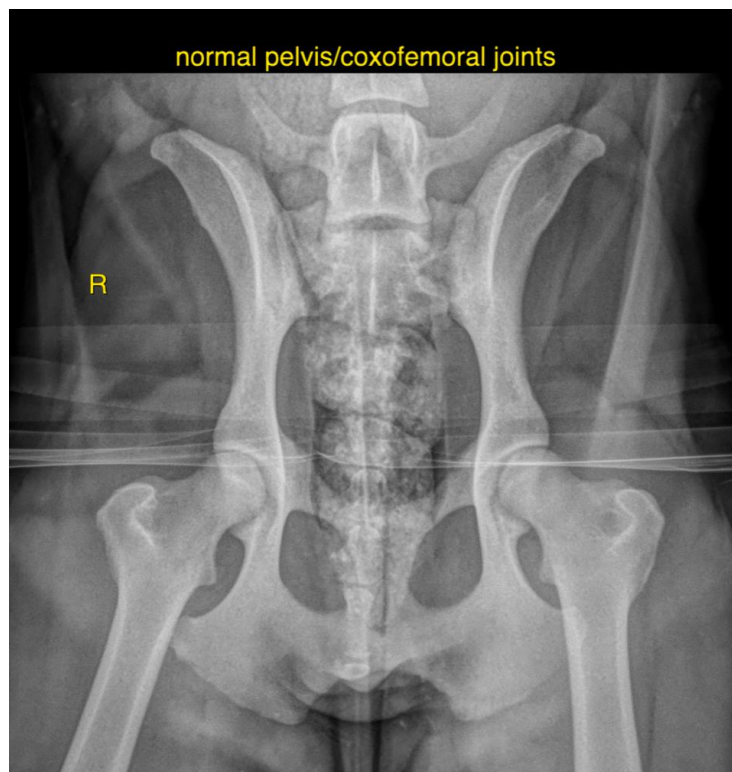
Kim Allyn, DVM

INVOICE

53525

DATE

8-17-22





PATIENT

Bentley Mumm

The information and recommendations provided are based on the images presented by the referring veterinarian/sonographer. No evaluation can be communicated regarding pathology that was not visible in the image/video clips provided.

SPECIES

Canine

Thank you for this referral. If the clinical or image interpretation does not parallel your findings or if I can be of any further assistance please contact me.

Sebastian Schaub, Sebastian Schaub, DVM, Dr. med. vet. DipECVDI
sebast.schaub@gmail.com

BREED

Australian Shepherd

SEX

MN

AGE

6 Years

INTERPRETED BY

Sebastian Schaub, DVM
Dr. med. vet. DipECVDI

HOSPITAL NAME

Elizabeth Animal
Hospital

REFERRING VET

Kim Allyn, DVM

INVOICE

53525

DATE

8-17-22