



PATIENT PRESENTING CLINICAL SIGNS

Sammi Scerbo History: CHRONIC OTITIS
Abnormal PE/Chem/CBC/UA Results:

SPECIES RADIOGRAPHIC STUDY OF THE SKULL

Canine A complete set of radiographs of the skull is provided for review. Images are provided in JPEG file format.

BREED RADIOGRAPHIC FINDINGS

Shih Poo The left external ear canal is moderately to markedly narrowed. The osseous lining of the left tympanic bulla is moderately thickened and smooth. The left tympanic bulla presents a moderate increased radiopacity in the lateral projection. A generalized left sided periauricular soft tissue swelling is visible.

SEX

Spayed Female The right external ear canal is aerated and the tympanic bulla is aerated with a smooth osseous lining. No additional abnormalities are appreciated.

AGE

8 Years

- Left sided irregular narrowed external ear canal with accompanying soft tissue swelling
- Evidence of left sided chronic otitis media

INTERPRETED BY INTERPRETATION OF THE FINDINGS & FURTHER RECOMMENDATIONS

Sebastian Schaub, DVM Dr. med. vet. DipECVDI The radiographic findings fit the history of left sided chronic otitis media with stenosis of the left external ear canal and evidence of periauricular swelling – likely secondary, rule out abscess formation or evidence of neoplastic transformation. There is evidence of accompanying left sided chronic otitis media. A total ear canal ablation including lateral bulla osteotomy might be beneficial.

HOSPITAL NAME

Tenaflly VC

REFERRING VET

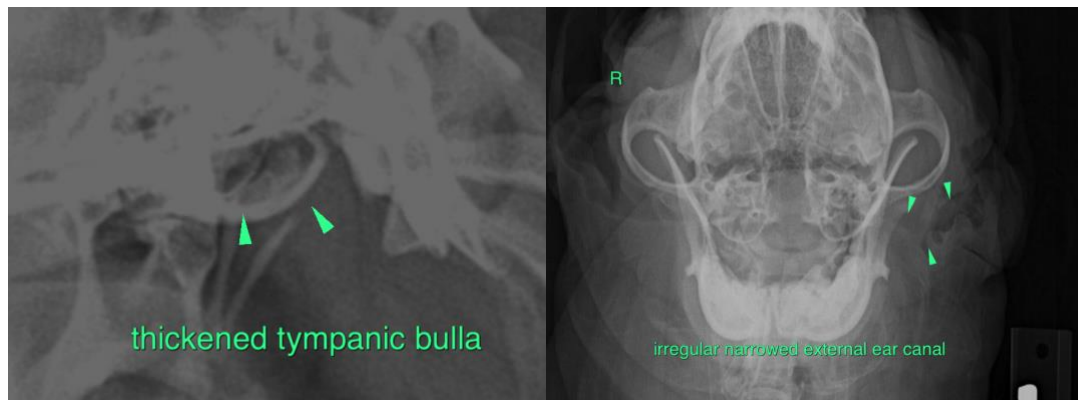
Ohad Barnea

INVOICE

12567

DATE

8/17/21





PATIENT

Sammi Scerbo

The information and recommendations provided are based on the images presented by the referring veterinarian. No evaluation can be communicated regarding pathology that was not visible in the image/video clips provided.

SPECIES

Canine

Thank you for this referral. If the clinical or image interpretation does not parallel your findings or if I can be of any further assistance please contact me.

Sebastian Schaub, Sebastian Schaub, DVM, Dr. med. vet. DipECVDI
sebast.schaub@gmail.com

BREED

Shih Poo

SEX

Spayed Female

AGE

8 Years

INTERPRETED BY

Sebastian Schaub,
DVM Dr. med. vet.
DipECVDI

HOSPITAL NAME

Tenaflly VC

REFERRING VET

Ohad Barnea

INVOICE

12567

DATE

8/17/21