



PATIENT PRESENTING CLINICAL SIGNS

Roxy Gorman History: dog bite on leg, limping
Abnormal PE/Chem/CBC/UA Results:

SPECIES RADIOGRAPHIC STUDY OF THE TARSAL JOINT

Canine A mediolateral projection of one tarsal joint is provided for review. No side markers are present.

RADIOGRAPHIC FINDINGS

BREED
Hound Mix The periarticular bones of the tarsal joint presents smooth osseous margins. There is no evidence of intra- or extracapsular soft tissue swelling of the tarsal joints.

SEX

Spayed Female

RADIOGRAPHIC DIAGNOSIS

- History of bite wound one hind limb with small gas bubble within the soft tissues caudal to the stifle joint
- Normal tarsal joint

AGE

7 Months

INTERPRETATION OF THE FINDINGS & FURTHER RECOMMENDATIONS

The tarsal joint is presents without abnormalities. Check for perforating wound at the caudal aspect of the respective stifle joint.

INTERPRETED BY

Sebastian Schaub,
DVM Dr. med. vet.
DipECVDI

HOSPITAL NAME

Rockaway AH

REFERRING VET

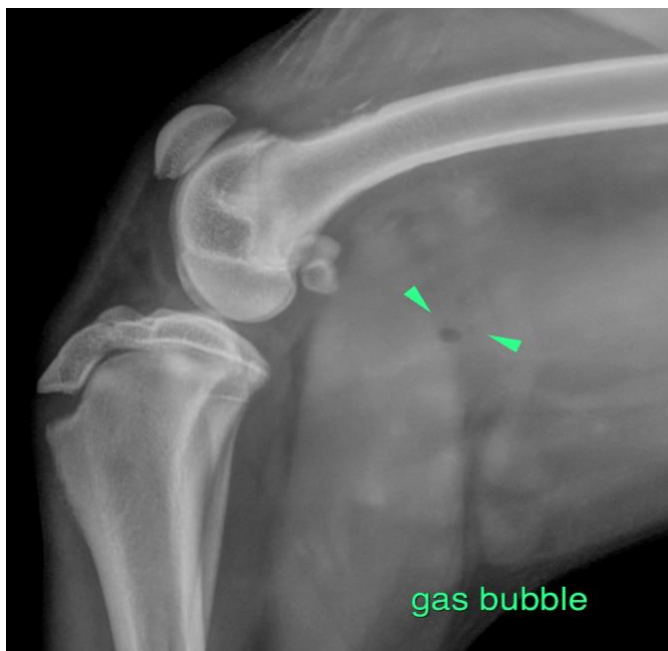
Dr. Maniar

INVOICE

12572

DATE

8/17/21





PATIENT

Roxy Gorman

The information and recommendations provided are based on the images presented by the referring veterinarian. No evaluation can be communicated regarding pathology that was not visible in the image/video clips provided.

SPECIES

Canine

Thank you for this referral. If the clinical or image interpretation does not parallel your findings or if I can be of any further assistance please contact me.

Sebastian Schaub, Sebastian Schaub, DVM, Dr. med. vet. DipECVDI
sebast.schaub@gmail.com

BREED

Hound Mix

SEX

Spayed Female

AGE

7 Months

INTERPRETED BY

Sebastian Schaub,
DVM Dr. med. vet.
DipECVDI

HOSPITAL NAME

Rockaway AH

REFERRING VET

Dr. Maniar

INVOICE

12572

DATE

8/17/21