



PATIENT PRESENTING CLINICAL SIGNS

Burnsey Burns P presented on 8/11 for an exam due to having a large ulcerated mass. O says it changed over the last week. CT scan performed prior to mass removal to check for metastasis

SPECIES COMPUTED TOMOGRAPHY OF THE THORAX AND ABDOMEN

Canine A high resolution pre- and post-contrast CT study of the abdomen and a plain CT study of the thorax are provided for review.

COMPUTED TOMOGRAPHIC FINDINGS

BREED Thorax

Mixed Breed The periarticular bones of the left shoulder joint present moderate osteophyte new bone formation.

SEX The sternal, cranial mediastinal and tracheobronchial lymph nodes are small elongated with a normal short-to-long-axis-ratio is < 0.5, the attenuation pattern is uniform.

MN The cardiovascular structures including the pulmonary vasculature are within normal limits.

AGE The bronchial tree presents with regular branching and tapers uniformly towards the periphery as expected, the bronchial walls are thin and smooth. The bronchus-to-artery ratio is within normal limits.

13 Years The lung parenchyma presents the expected architecture and attenuation behavior, but zones of dystelectasis of the dorsal dependent aspects of the lung and randomly distributed interspersed punctuate mineralization.

INTERPRETED BY

Small incidental gas pockets are seen within the esophageal lumen, there is no evidence of abnormal dilation.

Abdomen

HOSPITAL NAME

The serosal fat presents normal attenuation behavior. There is no evidence of peritoneal effusion or peritonitis.

Catskill Veterinary Services, PLLC

Both kidneys present within normal limits for size, shape and organ architecture. After contrast administration a bilaterally symmetric and uniform nephro- and pyelogram is noted.

The adrenal glands are within normal limits for size, shape and organ architecture.

REFERRING VET

Dr. Sarah Wright

The liver presents with normal shape, even surface, uniformly attenuating parenchyma and homogeneous contrast enhancement, unremarkable.

The spleen is normal in size and shape, the splenic parenchyma is uniform soft tissue attenuating. Post contrast administration in the body of the spleen, a nodular irregular mild contrast enhancing nodular lesion is appreciated.

INVOICE

59754 The pancreas is evenly contoured, the pancreatic parenchyma is homogeneous and presents uniform contrast enhancement.

DATE

8-16-23

The position, delineation, wall and content of the gastrointestinal tract are considered within normal limits throughout.

Protruding from the cutaneous surface of the right lateral abdominal wall, level with L4, a prominent, pedunculated soft tissue mass is appreciated, measuring approximately 1.7 x 2.3 x 4.3 cm. The



PATIENT subcutaneous tissue level with the cutaneous wart like lesion presents focal soft tissue striation.

Burnsey Burns Level with the intervertebral disc spaces L5/L6 to L7/S1, disc material is protruding into the vertebral canal, occupying approximately up to 15% of the cross-sectional area of the vertebral canal at the same level.

SPECIES **COMPUTED TOMOGRAPHIC DIAGNOSIS**

- Canine
 - Pedunculated soft tissue mass right abdominal wall
 - Contrast enhancing intraparenchymal splenic lesion
 - Degenerative osteoarthritis left shoulder joint
- BREED**
 - Intervertebral disc protrusion L5/L6 to L7/S1 without compression of the cauda equina fibers
 - Pulmonary osteomas
- Mixed Breed
 - No evidence of pulmonary metastatic disease

SEX **INTERPRETATION OF THE FINDINGS & FURTHER RECOMMENDATIONS**

MN The contrast enhancing splenic intraparenchymal nodular lesion is most consistent with nodular hyperplasia, FNA sampling of the spleen can be used to rule out diffuse infiltrative disease.

AGE

13 Years

INTERPRETED BY

Sebastian Schaub, DVM
Dr. med. vet. DipECVDI

HOSPITAL NAME

Catskill Veterinary Services, PLLC

REFERRING VET

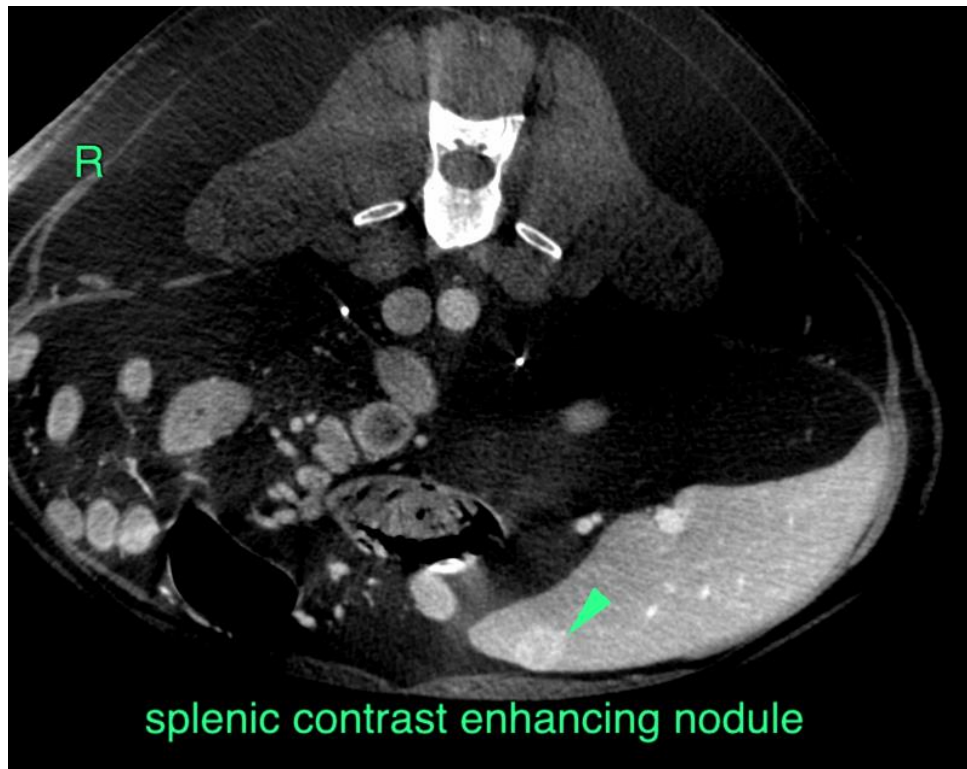
Dr. Sarah Wright

INVOICE

59754

DATE

8-16-23





PATIENT

Burnsey Burns

SPECIES

Canine

BREED

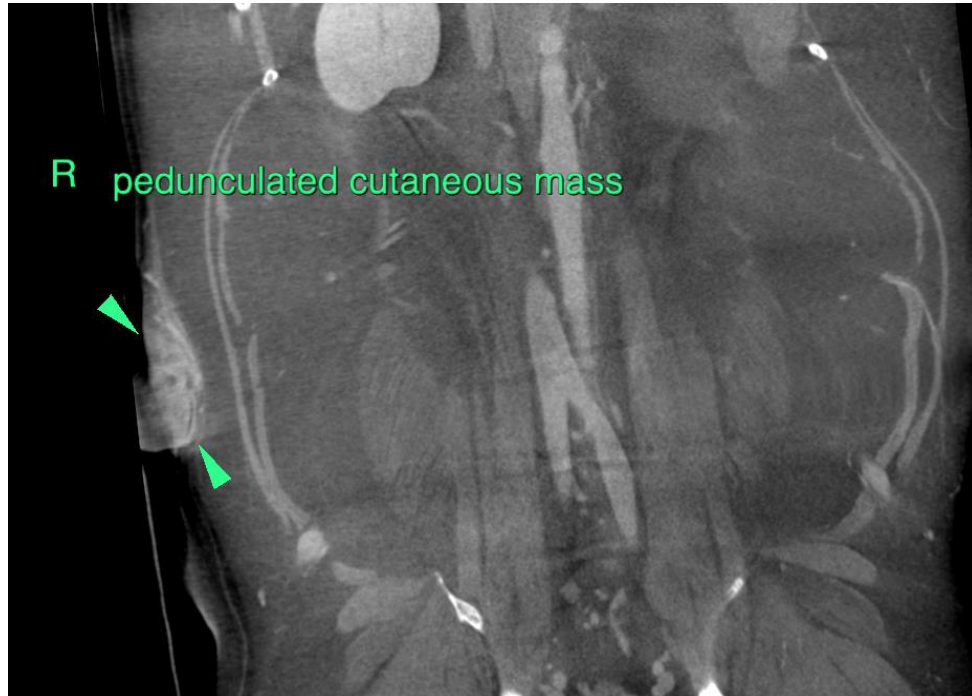Mixed Breed

SEX

MN

AGE

13 Years



INTERPRETED BY

Sebastian Schaub, DVM
Dr. med. vet. DipECVDI

The information and recommendations provided are based on the images presented by the referring veterinarian/sonographer. No evaluation can be communicated regarding pathology that was not visible in the image/video clips provided.

HOSPITAL NAME

Catskill Veterinary
Services, PLLC

Thank you for this referral. If the clinical or image interpretation does not parallel your findings or if I can be of any further assistance please contact me.

Sebastian Schaub, Sebastian Schaub, DVM, Dr. med. vet. DipECVDI
info@sonopath.com

REFERRING VET

Dr. Sarah Wright

INVOICE

59754

DATE

8-16-23