



PATIENT

Manfredo Melville

PRESENTING CLINICAL SIGNS

Since last night, has been reverse sneezing consistently, appears congested and cannot get comfortable. On exam - his neck and calvarium seem slightly painful. CT to investigate for any nasal or other intracranial causes for congestion/un-comfortability and pain around neck

SPECIES

Canine

COMPUTED TOMOGRAPHY OF THE SKULL

A high resolution pre- and post-contrast CT study of the skull is provided for review.

BREED

Chihuahua

COMPUTED TOMOGRAPHIC FINDINGS

The tooth elements 101, 102, 201-203, 205, 301-305, 311, 401-403, 405 and 411 are absent .Triadan 105-107, 206-207 and the distal root of triadan 307&407 present a moderate widening of the periodontal space and horizontal bone loss.

SEX

Male Neutered

A small amount of fluid attenuating material is attached to the nasal mucosal lining, the mucosal lining along the ventral nasal meatus bilaterally is moderately thickened.

Both temporomandibular joints present congruent joint spaces with even subchondral bone surfaces and are considered within normal limits.

AGE

14 Years

Both tympanic bullae are aerated, the mucosal lining is not seen, the bony wall is smooth and thin. The external ear canals are within normal limits.

The brain presents no deviation from normal anatomy and symmetry. The brain parenchyma is homogeneous and within normal limits for attenuation and distribution of contrast enhancement. The ventricular system is non-dilated and symmetric.

INTERPRETED BY

Sebastian Schaub, DVM
Dr. med. vet. DipECVDI

The submandibular and medial retropharyngeal lymph nodes are small and elongated with a normal short-to-long-axis-ratio is < 0.5, the attenuation and contrast enhancement pattern is uniform.

HOSPITAL NAME

Scottsdale Veterinary
Clinic

COMPUTED TOMOGRAPHIC DIAGNOSIS

- Periodontal disease 105-107, 206-207, 307&407
- Mild rhinitis
- Multiple absent teeth

REFERRING VET

Dr. Hertz

INTERPRETATION OF THE FINDINGS & FURTHER RECOMMENDATIONS

An underlying cause for the rhinitis cannot be appreciated, there is no evidence of macroscopic oronasal fistula formation, anyway a complete dental workup appears beneficial to rule out dental disease as trigger for the rhinitis. Non-specific rhinitis is a possibility as well (e.g. lymphocytic plasmocytic, eosinophilic).

INVOICE

53516

DATE

8-16-22



PATIENT

Manfredo Melville

SPECIES

Canine

BREED

Chihuahua

SEX

Male Neutered

AGE

14 Years

INTERPRETED BY

Sebastian Schaub, DVM
Dr. med. vet. DipECVDI

HOSPITAL NAME

Scottsdale Veterinary
Clinic

REFERRING VET

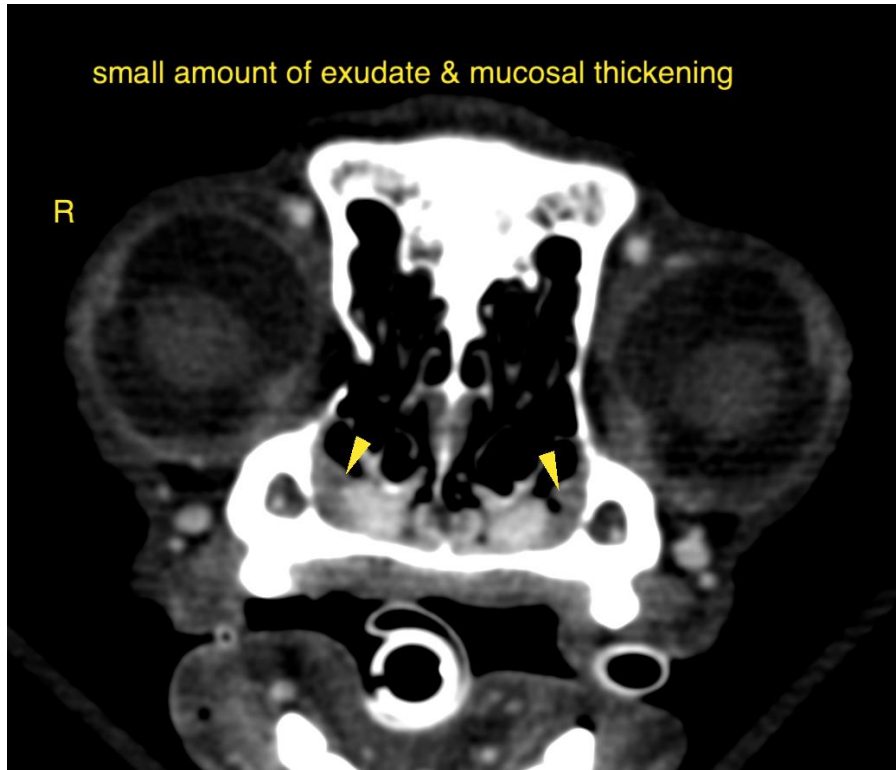
Dr. Hertz

INVOICE

53516

DATE

8-16-22



small amount of exudate & mucosal thickening

The information and recommendations provided are based on the images presented by the referring veterinarian/sonographer. No evaluation can be communicated regarding pathology that was not visible in the image/video clips provided.

Thank you for this referral. If the clinical or image interpretation does not parallel your findings or if I can be of any further assistance please contact me.

Sebastian Schaub, Sebastian Schaub, DVM, Dr. med. vet. DipECVDI
sebast.schaub@gmail.com