

**PATIENT**

Gibbs Casciano

PRESENTING CLINICAL SIGNS

Swallowing "hard" and gagging. Looks like he is swallowing a part of himself, maybe his tongue "fleshy thing". Unusual soft tissue opacity in area of esophagus/proximal to trachea.

SPECIES

Canine

RADIOGRAPHIC STUDY OF THE NECK

Radiographs of the neck in two orthogonal imaging planes are provided for review.

BREED

Labrador Mix

RADIOGRAPHIC FINDINGS

The oropharynx is aerated, and the soft palate and laryngeal structures are accentuated by the surrounding gas.

Between the cervical spine and the tracheal, level with C3&C4, gas is demarcating the cranial and caudal margins of a fusiform appearing structure, measuring approximately 5.7 cm in length and 1.6 cm in height.

SEX

Male Neutered

The trachea presents with the expected course and height with smooth margins.

RADIOGRAPHIC DIAGNOSIS

- Possible fusiform soft tissue structure region to proximal esophagus

AGE

9 Years, 8 Months

INTERPRETATION OF THE FINDINGS & FURTHER RECOMMENDATIONS

The unusual soft opacity accentuated by gas between the trachea and the cervical spine can be caused by gas delineating a prominent mucosal esophageal fold, thickened mural esophageal fold (e.g inflammatory versus neoplastic), rare esophageal polyp or esophageal foreign body in an unusual position. A retropharyngeal lesion outlined by gas (e.g. stick injury) is a consideration as well. For further workup, either a positive contrast esophagogram, using iodinated contrast media or CT study of the neck can be used for further definition. Evaluation of the larynx/pharynx under general anesthesia including evaluation of the proximal esophagus is recommended as well.

INTERPRETED BY

Sebastian Schaub, DVM
Dr. med. vet. DipECVDI

HOSPITAL NAME

Ramapo Valley
Animal Hospital

REFERRING VET

Dr. Manohar Katara

INVOICE

53513

DATE

8-16-22



PATIENT

Gibbs Casciano

SPECIES

Canine

BREED

Labrador Mix

SEX

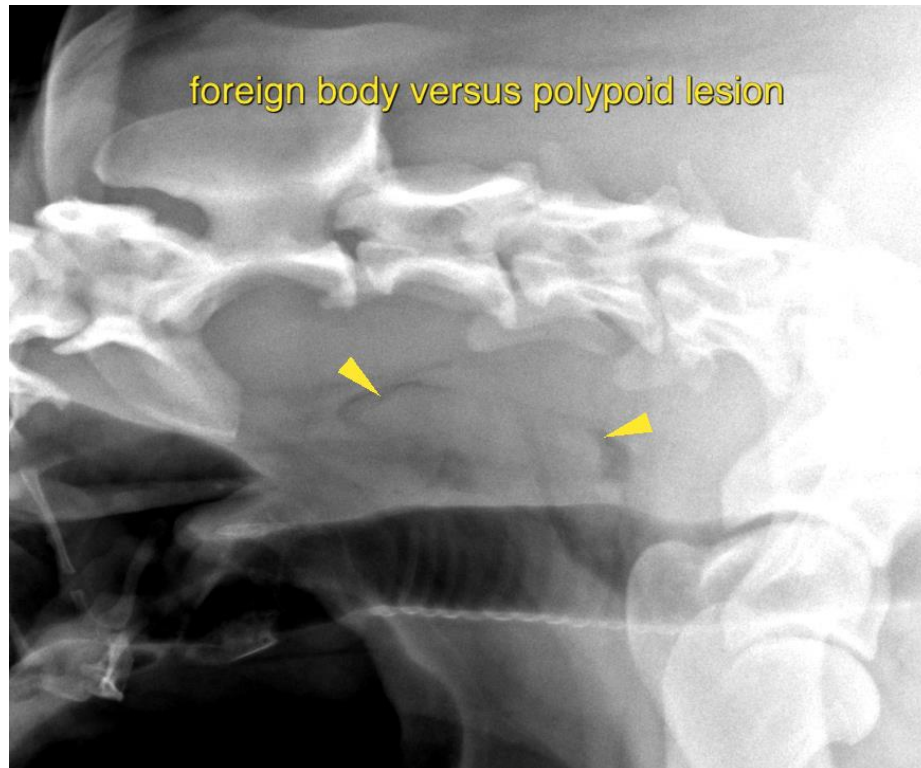
Male Neutered

AGE

9 Years, 8 Months

INTERPRETED BY

Sebastian Schaub, DVM
Dr. med. vet. DipECVDI



HOSPITAL NAME

Ramapo Valley
Animal Hospital

REFERRING VET

Dr. Manohar Katara

INVOICE

53513

DATE

8-16-22

The information and recommendations provided are based on the images presented by the referring veterinarian/sonographer. No evaluation can be communicated regarding pathology that was not visible in the image/video clips provided.

Thank you for this referral. If the clinical or image interpretation does not parallel your findings or if I can be of any further assistance please contact me.

Sebastian Schaub, Sebastian Schaub, DVM, Dr. med. vet. DipECVDI
sebast.schaub@gmail.com