



**PATIENT PRESENTING CLINICAL SIGNS**

**Patient:** Penguin Marine  
**History:** Intermittent vomiting of bile x 2 weeks. Does eat foreign things on trail. Also has had intermittent soft stool. Also seems less energetic bordering on lethargic this week.  
**Abnormal PE/Chem/CBC/UA Results:** fecal pending

**SPECIES RADIOGRAPHIC STUDY OF THE ABDOMEN**

**Species:** Canine  
 Radiographs of the abdomen is provided for review.

**BREED RADIOGRAPHIC FINDINGS**

**Breed:** Border Collie  
 The surrounding bony structures are within normal limits.

**SEX:** No abnormalities of the extraabdominal soft tissues are noted. The abdominal wall is smooth and thin.

**Sex:** Intact Female  
 The serosal detail is decreased, due to the age of the patient.

The liver is appropriate in position, size and presents uniform opacity.

**AGE:** The splenic head is in the anticipated position and within normal limits for size and opacity. The splenic body and tail are considered normal for position, size, shape and opacity.

**Age:** 4 Months

The kidneys are effaced by superimposed structures of the gastrointestinal tract. The urinary bladder is in its anticipated position. No radiopaque calculi are noted throughout the upper and lower urinary tract.

**INTERPRETED BY**

Sebastian Schaub,  
 DVM Dr. med. vet.  
 DipECVDI

The stomach is in its anticipated position and contains a mild amount of gas.

**HOSPITAL NAME**

Pinebrook AH

The small intestinal loops are of even diameter and non-dilated, a small to moderate amount of gas is seen within the small intestinal loops.

**RADIOGRAPHIC DIAGNOSIS**

**REFERRING VET**

Dr. Britt Dubil

- Empty stomach
- Mild gas pattern intestinal tract

**INTERPRETATION OF THE FINDINGS & FURTHER RECOMMENDATIONS**

**INVOICE**

12549

There is no evidence of radiopaque foreign material or signs for gastrointestinal mechanical obstruction. In conjunction with the history gastritis or gastroenteritis are potentials here. Recommend empirical management. If clinical signs are refractory to therapy or deteriorate, follow up radiographs or an abdominal ultrasound examination are recommended.

**DATE**

8/16/21

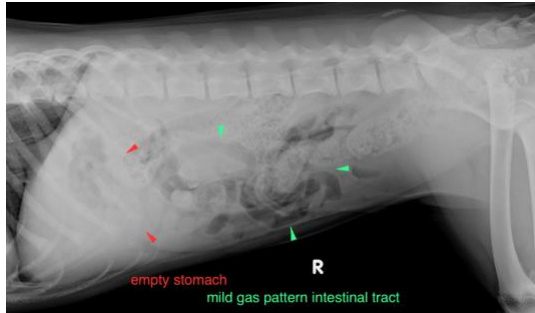


**PATIENT**

Penguin Marine

**SPECIES**

Canine



**BREED**

Border Collie

**The information and recommendations provided are based on the images presented by the referring veterinarian. No evaluation can be communicated regarding pathology that was not visible in the image/video clips provided.**

**SEX**

Intact Female

Thank you for this referral. If the clinical or image interpretation does not parallel your findings or if I can be of any further assistance please contact me.

**Sebastian Schaub**, Sebastian Schaub, DVM, Dr. med. vet. DipECVDI  
sebast.schaub@gmail.com

**AGE**

4 Months

**INTERPRETED BY**

Sebastian Schaub,  
DVM Dr. med. vet.  
DipECVDI

**HOSPITAL NAME**

Pinebrook AH

**REFERRING VET**

Dr. Britt Dubil

**INVOICE**

12549

**DATE**

8/16/21