



PATIENT PRESENTING CLINICAL SIGNS

Storm Petzen P presents for a 1-2 week duration of wheezing, mild increase in respiratory effort, and lethargy. Mild increased BV sounds X4 with a mild increased respiratory effort on exam. No heart murmur auscultated. MM pk/moist/CRT < 1 second.

SPECIES Abnormal PE/Chem/CBC/UA Results: None performed (CBC, Chem 28, UA, T4, HWT, BNP recommended and declined)

Feline

RADIOGRAPHIC STUDY OF THE THORAX

Radiographs of the thorax in three imaging planes are provided for review.

BREED

DSH

RADIOGRAPHIC FINDINGS

The surrounding bony structures are within normal limits.

The extrathoracic soft tissues present homogeneous without abnormalities.

SEX

FS

The heart is of normal size and shape, there is no evidence of cardiac chamber or vascular enlargement.

The pulmonary vasculature is within normal limits.

AGE

16 Years

The trachea is normal in diameter and presents the anticipated course. The luminal outline of the trachea is smooth.

A generalized mild to moderate increased visibility of the bronchial walls is appreciated.

The lung parenchyma presents the expected architecture and opacity; the intrapulmonary vascular branching is seen up to the third order lung vessels.

INTERPRETED BY

Sebastian Schaub, DVM
Dr. med. vet. DipECVDI

The diaphragm is well delineated with even surface and the expected mild cranial bulging of the diaphragmatic cupola.

HOSPITAL NAME

Nimbus Pet Hospital

RADIOGRAPHIC DIAGNOSIS

- Mild bronchial lung pattern

INTERPRETATION OF THE FINDINGS & FURTHER RECOMMENDATIONS

REFERRING VET

Saum Hadi

The bronchial lung pattern is suggestive for feline bronchial disease – commonly primary allergic in origin ± bacterial superinfection. In few cases the bronchial pattern can be a sequela to bronchogenic carcinoma.

The cardiovascular structures are considered within normal limits.

INVOICE

59724

DATE

8-15-23



PATIENT

Storm Petzen

SPECIES

Feline

BREED

DSH

SEX

FS

AGE

16 Years

INTERPRETED BY

Sebastian Schaub, DVM
Dr. med. vet. DipECVDI

HOSPITAL NAME

Nimbus Pet Hospital

REFERRING VET

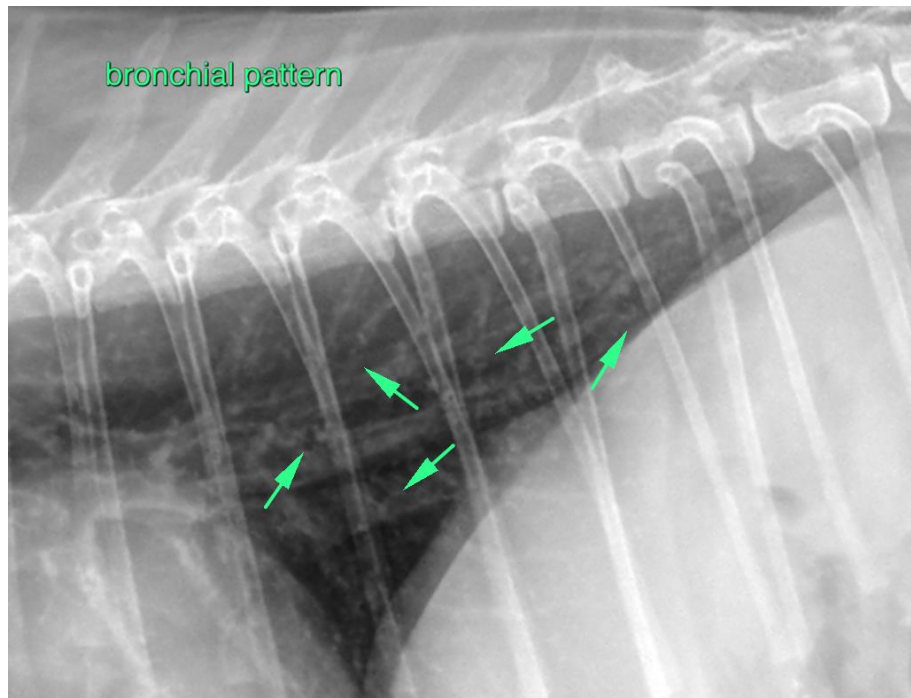
Saum Hadi

INVOICE

59724

DATE

8-15-23



The information and recommendations provided are based on the images presented by the referring veterinarian/sonographer. No evaluation can be communicated regarding pathology that was not visible in the image/video clips provided.

Thank you for this referral. If the clinical or image interpretation does not parallel your findings or if I can be of any further assistance please contact me.

Sebastian Schaub, Sebastian Schaub, DVM, Dr. med. vet. DipECVDI
info@sonopath.com