



PATIENT PRESENTING CLINICAL SIGNS

Raja Stegans Hx significant arthritis. Has had imaging before, recently pet has been limping more and seemingly more painful. Recently restarted Adequan injections, adjusted medications and increased laser therapy and pet seems overall better per O/pet-sitter. Sent both radiology studies from 10/6/22 and today (8/15/23), previous diagnosis in 'notes' section an was read by sonopath radiologist. 7 images are from todays study, 5 images are from 10/2022.

SPECIES

Canine Abnormal PE/Chem/CBC/UA Results: Hx elevated liver enzymes (mild)

RADIOGRAPHIC STUDY OF THE FRONT AND HIND LIMBS

BREED

A complete set of radiographs of the front and hind limbs is provided for review.

Boston Terrier Mix

RADIOGRAPHIC FINDINGS

Front limbs

SEX

In the radiographic study of the shoulder joints, the contralateral shoulder joint is superimposed on the caudal aspect respectively. The osseous and surrounding soft tissue structures of both shoulder joints present without overt abnormalities.

FS

AGE

The periarticular bones of both elbow joints present moderate osteophyte new bone formation, R>L. The contour of the medial coronoid process of both elbow joints is ill-defined and the tip cannot be delineated.

12.5 Years

The osseous and surrounding soft tissue structures of the carpal joints present without abnormalities.

INTERPRETED BY

The metacarpophalangeal joint of the second & fifth phalanx of the right front paw and the second to fifth phalanx of the left front paw present moderate osteophyte new bone formation.

Sebastian Schaub, DVM
Dr. med. vet. DipECVDI

The proximal interphalangeal joint of the second and third digit of the left front paw present mild osteophyte new bone formation.

HOSPITAL NAME

Pelvis & Hind limb

Long Valley Animal Hospital

The periarticular bones of the left coxofemoral joint present advanced osteophyte new bone formation, distorting the left femoral head. The left acetabular groove is shallow and the center of the left femoral heads is lateral to the dorsal acetabular rim. The joint space of the left coxofemoral joint is diverging.

REFERRING VET

The periarticular bones of both stifle joints present mild osteophyte new bone formation, R>L. No overt intracapsular soft tissue swelling of the stifle joints is appreciated.

Dr. Stephanie Welch

The periarticular bones of both tibiotarsal joints present moderate osteophyte new bone formation and signs of mild intracapsular soft tissue swelling.

INVOICE

Osteophyte formation is seen along the dorsal aspect of the intertarsal joints.

59713

RADIOGRAPHIC DIAGNOSIS

DATE

8-15-23

- Degenerative osteoarthritis elbow joints bilaterally, R>L
- Suspect coronoid disease elbow joints bilaterally
- Degenerative osteoarthritis multiple metacarpophalangeal joints both front paws– see description
- Degenerative osteoarthritis proximal interphalangeal joint second and third digit left front paw



PATIENT

Raja Stegans

- Mild degenerative osteoarthritis stifle joints bilaterally
- Moderate degenerative osteoarthritis tibiotarsal joint bilaterally with mild articular swelling
- Advanced degenerative osteoarthritis left coxofemoral joints, due to hip dysplasia.

SPECIES

Canine

INTERPRETATION OF THE FINDINGS & FURTHER RECOMMENDATIONS

The radiographic study of the front and hind limbs presents signs of degenerative joint disease of multiple joints, that can all contribute to lameness/pain. Findings need to be correlated with the findings of the clinical examination to further specify the clinically most relevant joints.

BREED

Boston Terrier Mix

SEX

FS

AGE

12.5 Years

INTERPRETED BY

Sebastian Schaub, DVM
Dr. med. vet. DipECVDI

HOSPITAL NAME

Long Valley Animal
Hospital

REFERRING VET

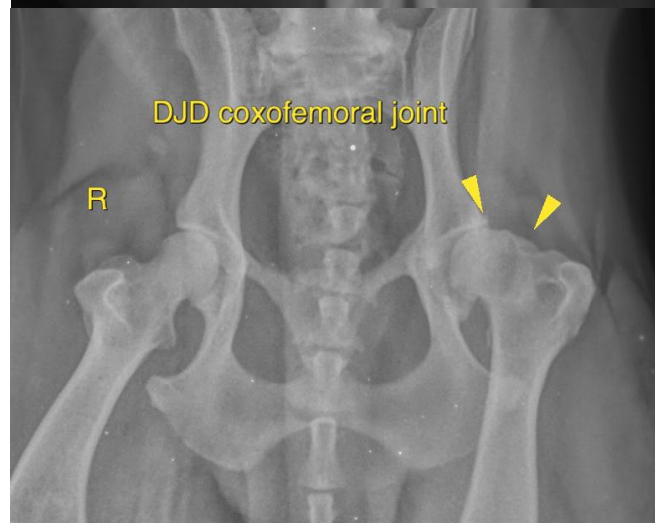
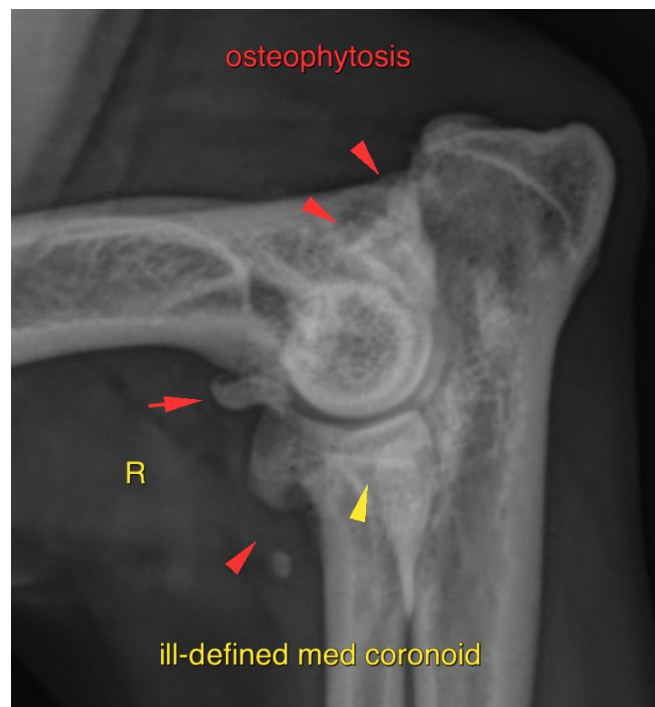
Dr. Stephanie Welch

INVOICE

59713

DATE

8-15-23





PATIENT

Raja Stegans

SPECIES

Canine

BREED

Boston Terrier Mix

SEX

FS

AGE

12.5 Years

INTERPRETED BY

Sebastian Schaub, DVM
Dr. med. vet. DipECVDI

HOSPITAL NAME

Long Valley Animal
Hospital

REFERRING VET

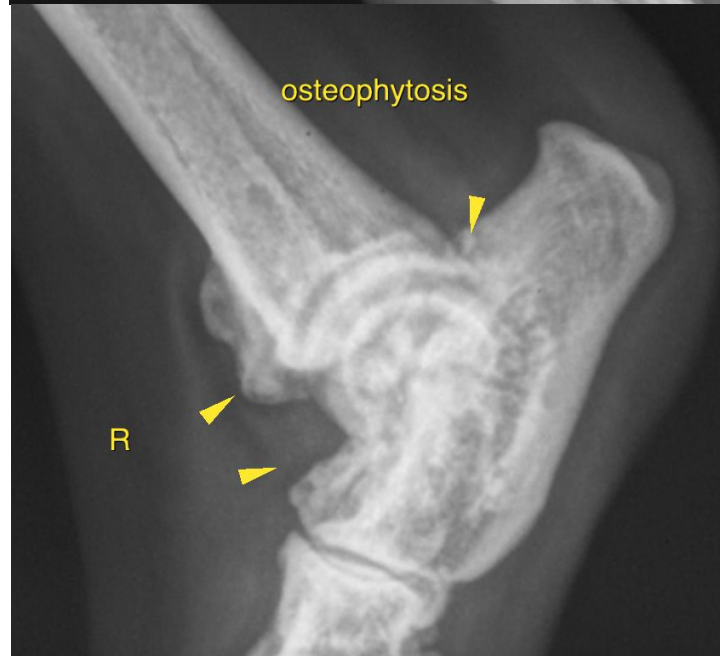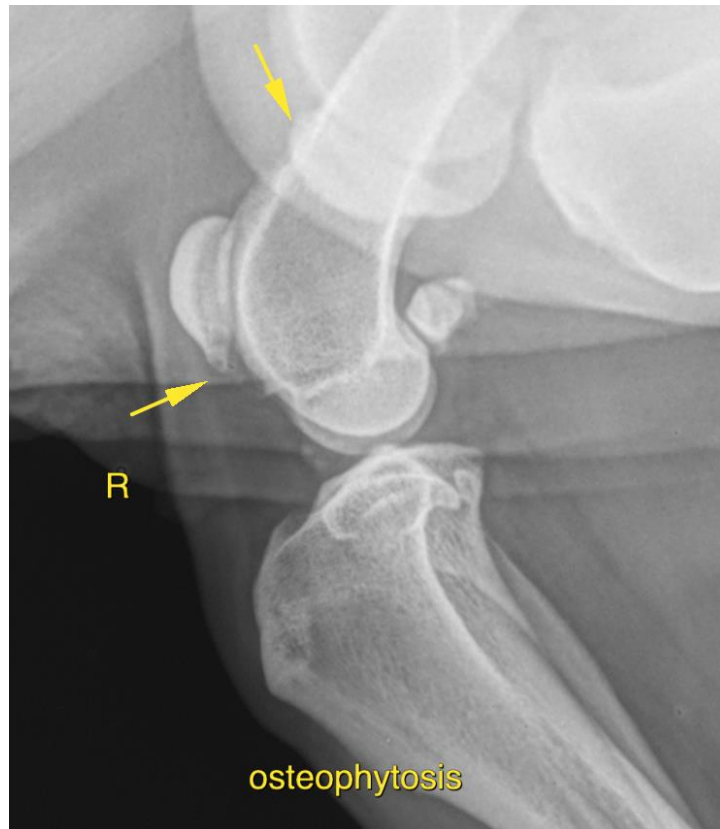
Dr. Stephanie Welch

INVOICE

59713

DATE

8-15-23





PATIENT

Raja Stegans

SPECIES

Canine

BREED

Boston Terrier Mix

SEX

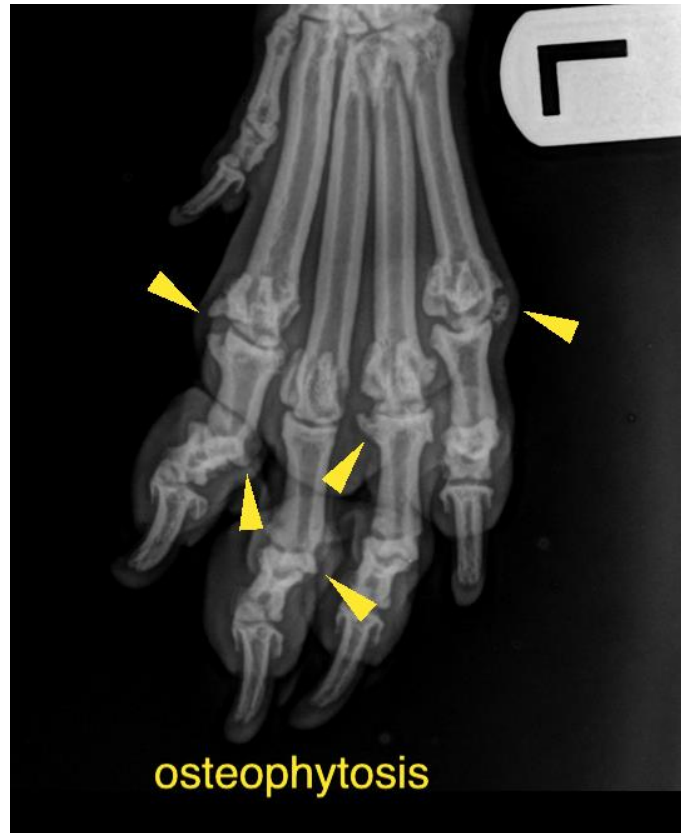
FS

AGE

12.5 Years

INTERPRETED BY

Sebastian Schaub, DVM
Dr. med. vet. DipECVDI



HOSPITAL NAME

Long Valley Animal
Hospital

REFERRING VET

Dr. Stephanie Welch

The information and recommendations provided are based on the images presented by the referring veterinarian/sonographer. No evaluation can be communicated regarding pathology that was not visible in the image/video clips provided.

Thank you for this referral. If the clinical or image interpretation does not parallel your findings or if I can be of any further assistance please contact me.

Sebastian Schaub, Sebastian Schaub, DVM, Dr. med. vet. DipECVDI
info@sonopath.com

INVOICE

59713

DATE

8-15-23