



PATIENT PRESENTING CLINICAL SIGNS

Bryant Kneisley 4 day duration of lethargy, partial anorexia, occasional vomiting, diarrhea.
 Abnormal PE/Chem/CBC/UA Results: Increased ALT, ALP, k+. AUS interpretation is pending.

SPECIES RADIOGRAPHIC STUDY OF THE THORAX & ABDOMEN

Canine An overview study including the thorax and abdomen in three imaging planes is provided for review.

RADIOGRAPHIC FINDINGS

BREED Thorax

Terrier The surrounding bony structures are within normal limits.

The extrathoracic soft tissues present homogeneous without abnormalities.

SEX The heart is of normal size and shape, there is no evidence of cardiac chamber or vascular enlargement.
 The pulmonary vasculature is within normal limits.

Male Neutered The cranial mediastinum presents the expected soft tissue opacity. The mediastinal width is less than twice the width of the vertebral column at the same level.

AGE The trachea is normal in diameter and presents the anticipated course. The luminal outline of the trachea is smooth.

13 Years The bronchial tree presents with thin walls and tapers uniformly towards the periphery as expected.

INTERPRETED BY

The lung parenchyma presents the expected architecture and opacity; the intrapulmonary vascular branching is seen up to the third order lung vessels. The nodular soft tissue opacities seen in the cranial aspect of the right caudal lung lobe – adjacent to the heart – are considered as end-on projection of pulmonary vessels.

Sebastian Schaub, DVM
 Dr. med. vet. DipECVDI

HOSPITAL NAME

The diaphragm is well delineated with even surface and the expected mild cranial bulging of the diaphragmatic cupola.

Friendship Springs
 Veterinary Care

Abdomen

The vertebral endplates of the lumbosacral junction present mild spondylosis formation.

REFERRING VET

No abnormalities of the extraabdominal soft tissues are noted. The abdominal wall is smooth and thin.

Trae Cutchin

The serosal detail is lost and the margins of the abdominal organs are effaced by soft tissue material..

The liver is appropriate in position appears normal in size as no overt mass effect on the stomach is appreciated.

INVOICE

The spleen cannot be delineated.

59718

A small amount of irregular mineral opaque material is appreciated in the imaging plane of the renal pelvis bilaterally.

DATE

The stomach is in its anticipated position and presents normal content.

8-15-23

The small intestinal loops are of even diameter and non-dilated, a small amount of gas is seen within the small intestinal loops and considered within normal limits.



PATIENT

Bryant Kneisley The colon is seen in the expected position and is nearly empty.

RADIOGRAPHIC DIAGNOSIS

SPECIES

Canine

- Suspect mild peritoneal effusion effacing margins of the abdominal organs
- Nephrolithiasis
- Normal thorax

BREED

Terrier

INTERPRETATION OF THE FINDINGS & FURTHER RECOMMENDATIONS

The radiographic study presents only non-specific abnormalities. The decreased serosal detail, with effacement of the margins of the abdominal organs can indicate peritoneal effusion/peritonitis. Rule out underlying pancreatitis for the acute presenting clinical signs – if not done so yet, blood work should be complemented by cpl.

SEX

Male Neutered

An abdominal ultrasound examination has already been performed, regarding the history.

AGE

13 Years

INTERPRETED BY

Sebastian Schaub, DVM
Dr. med. vet. DipECVDI

HOSPITAL NAME

Friendship Springs
Veterinary Care

REFERRING VET

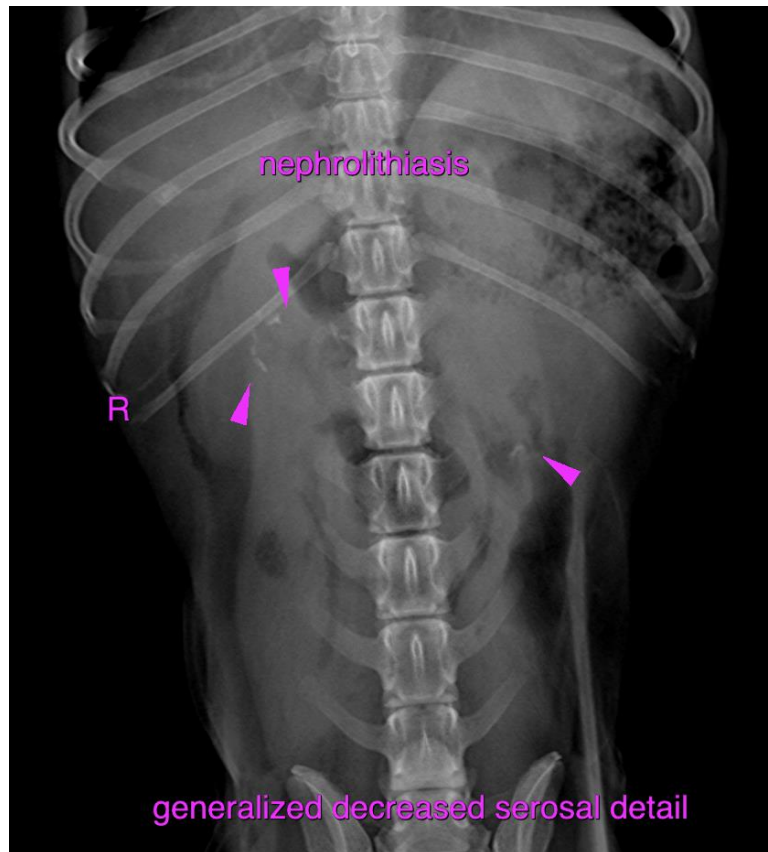
Trae Cutchin

INVOICE

59718

DATE

8-15-23





PATIENT

Bryant Kneisley

SPECIES

Canine

BREED

Terrier

SEX

Male Neutered

AGE

13 Years

INTERPRETED BY

Sebastian Schaub, DVM
Dr. med. vet. DipECVDI

HOSPITAL NAME

Friendship Springs
Veterinary Care

REFERRING VET

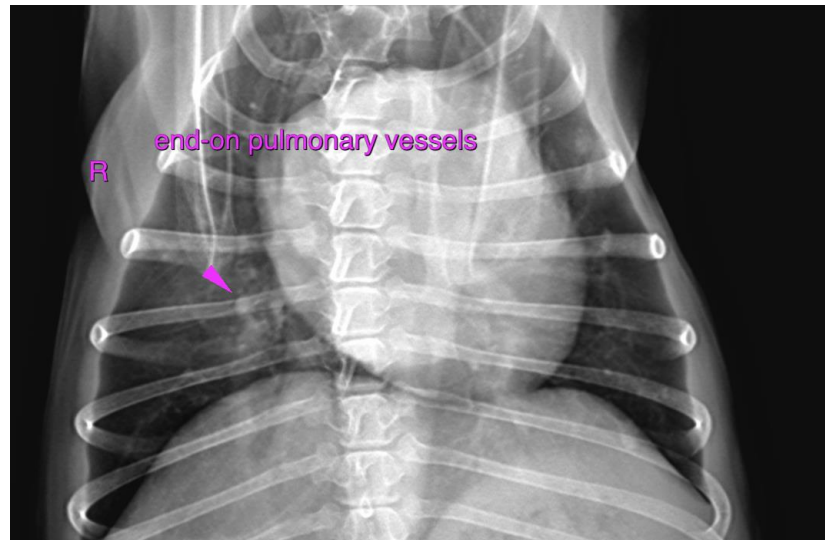
Trae Cutchin

INVOICE

59718

DATE

8-15-23



The information and recommendations provided are based on the images presented by the referring veterinarian/sonographer. No evaluation can be communicated regarding pathology that was not visible in the image/video clips provided.

Thank you for this referral. If the clinical or image interpretation does not parallel your findings or if I can be of any further assistance please contact me.

Sebastian Schaub, Sebastian Schaub, DVM, Dr. med. vet. DipECVDI
info@sonopath.com